The Mattress-Tension-Band Technique

A Knotless Double-Row Arthroscopic Rotator Cuff Repair

Pascal Boileau, MD, Nicolas Brassart, MD, Yannick Roussanne, MD, and Razvan Scobercea, MD

Abstract: Reestablishment of the native footprint during rotator cuff repair has been suggested to be important for optimizing fixation strength and healing potential. However, the complexity of most double-row repairs and the added surgical time remains a concern. We have developed a double-row rotator cuff repair that can be performed arthroscopically without the need to tie knots inside the joint. The technique, termed mattress-tension-band, is performed with 1 screwed anchor inserted medially at the articular margin and an impacted anchor inserted laterally on the greater tuberosity. An extracorporeally tied figure-of-8 knot forms the mattress suture medially, whereas a knotless tension-band is placed laterally. The mattress-tension-band technique restores the rotator cuff footprint anatomy in a simple, quick, and reproducible manner, thus reducing operative time. The main advantages are that there is no need to tie any knot inside the joint and that the only knot, tied extracorporeally, cannot slip, thereby improving initial strength and stiffness of the repair.

Key Words: arthroscopic rotator cuff repair, double-row, footprint

(*Tech Should Surg* 2009;10: 22–25)

Arthroscopic rotator cuff repair has undergone many advances in recent years. One current trend is the evolution from single-row to double-row repairs.[1–4] This technique involves placing 1 or more anchors medially adjacent to the articular margin and a second anchor laterally on the greater tuberosity. Biomechanical studies on double-row repairs have shown that they may provide 4 potential advantages. First, they provide better coverage of the rotator cuff footprint and increase the surface area available for tendon healing. Second, they enhance repair integrity because of the added number of anchors and sutures. Third, they increase repair stiffness by reducing tendon-bone interface motion.[5,6] Lastly, the medial mattress suture protects the healing zone on the tuberosity from the synovial fluid (which has been shown to impede healing of the tendon).

Although no proven clinical benefit has been established, studies have shown that double-row repairs provide better anatomical restoration and improved tendon healing over single-row repairs.[5] The disadvantage to double-row rotator cuff repairs is that they are technically demanding and time-consuming; double-row repair often means "double trouble" for the surgeon. As such, many surgeons are still reluctant to use this technique.

From the Department of Orthopeadic Surgery and Sports Traumatology, L'Archet Hospital, University of Nice-Sophia-Antipolis, Nice, France.
No benefits in any form have been received or will be received from a commercial party related directly or indirectly to the subject of this article. No funds were received in support of this study.
Reprints: Pascal Boileau, MD, Department of Orthopaedic Surgery and Sports Traumatology, L'Archet Hospital. University of Nice-Sophia-Antipolis, 151, route de St Antoine de Ginestière, 06202 Nice, France (e-mail: boileau.p@chu-nice.fr).

We have previously described a repair technique using a reverse mattress stitch with a single row of anchors placed on the lateral aspect of the greater tuberosity, termed the tension-band technique.[7,8] Although this technique provides complete coverage of the footprint and compression of the tendon on the footprint, the rate of complete healing of the tendon was only 70% on postoperative computed tomography arthrograms. In an effort to improve the rate of healing, we have developed a novel technique which maximizes tendon-to-bone compression and adds strength and rigidity to the repair by adding a medial row of anchors. The technique does not require any arthroscopic knot tying and is therefore simple, quick, and reproducible while providing a low-profile suture repair. This novel arthroscopic double-row repair technique has been termed the mattress-tension-band (MTB) technique. The purpose of this study is to describe this technique.

TECHNIQUE

Although our preference is to use the beach-chair position, this procedure can be done with the patient in the lateral decubitus position. Posterior and lateral portals are used mainly as viewing portals, whereas 2 anterior portals (anterolateral and anteromedial) are used as working portals. An additional fifth portal, located at the lateral aspect of the acromion (anterosuperior portal) is needed to place the medial anchor at the margin of the cartilage. Initial arthroscopic evaluation is achieved through a standard posterior portal. After intraarticular exploration has been completed, the arthroscope is switched to the lateral portal. Four steps are performed.

Step 1: Bursectomy and Mobilization of the Cuff

The subacromial space is cleared of adhesions, bursal tissue, and reactive synovitis using a motorized shaver (Smith&Nephew, Andover, MA) and/or electrocautery (VAPR; DePuy Mitek, Raynham, MA). The dimension, shape, and reducibility of the tear are evaluated. If the cuff is retracted and immobile, a systematic release is performed: (1) the superficial adhesions between the cuff and the coracoacromial arch are released, (2) a release of the tendon from the superior capsule is performed, and (3) the rotator interval is released by detaching the coracohumeral ligament from the base of the coracoid process. The goal is to allow a low-tension reduction of the supraspinatus tendon to its anatomical position on the upper surface of the greater tuberosity. Finally, a limited debridement of degenerative tendon margins is performed using a shaver or a basket biter.

Step 2: Preparing the Footprint of the Rotator Cuff

After adequate visualization, preparation, and release of the tear, the upper surface of the greater tuberosity is abraded widely with a shaver and burr (Acromionizer; Smith&Nephew) removing all soft tissue and cortical bone. The goal is to create a bleeding cancellous bone bed, not a trough, to aid tissue healing.

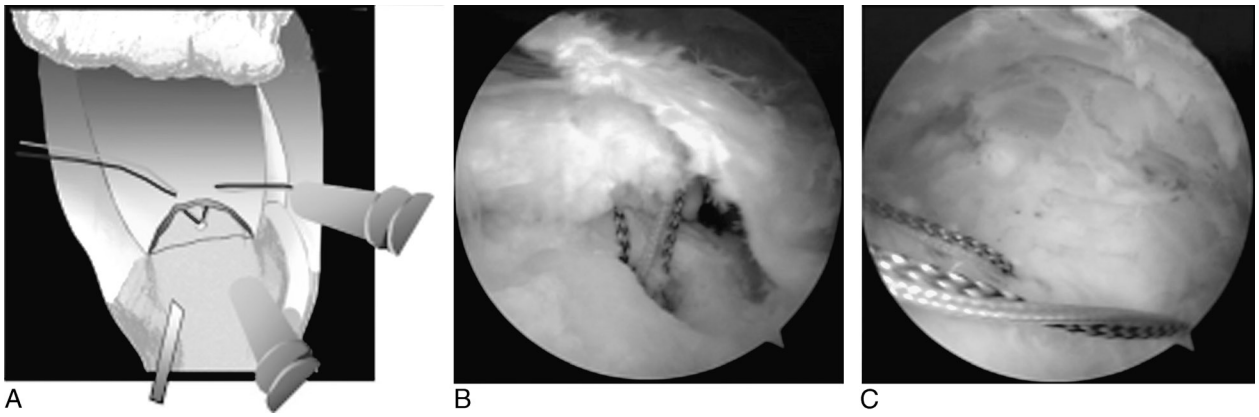

FIGURE 1. After insertion of the first screwed anchor medially (at the articular margin), the 2 sutures are passed through the cuff (A); both the superficial and the deep, delaminated layer of tendon must be taken with the medial stitch (B); bursal arthroscopic view showing the medial tendon bridge (approximately 7–8 mm) between sutures.

In addition, the lateral aspect of the greater tuberosity is cleared of all soft tissue and bursa.

Step 3: Medial Row of Sutures

A hole is drilled on the medial part of the greater tuberosity, at the articular margin, from the anterosuperior portal. The direction of the drilling should be oblique to reach the dense cancellous bone of the humeral head. A screwed bioabsorbable anchor with 2 sutures of different colors (blue and violette) is introduced in this hole (Spiralok; Mitek).

The 4 strands of sutures are passed through the medial part of the tendon (approximately 15–20 mm medial to the cuff margin) using a 45-degree angle suture hook (Linvatec, Key Largo, Fla). Because the torn tendon is often delaminated, great care should be made to take the deep, delaminated layer of tendon with the medial stitch. Using a grasper, traction is applied to the tendon with an inferolateral pull to facilitate passage of the suture hook through the tendon. A monofilament PDS suture (Johnson & Johnson, Ethicon, Somerville, NJ) is used to shuttle 2 suture limbs (one of each color) anteromedially through the tendon in retrograde fashion. The same maneuver is performed to shuttle the other 2 suture limbs (again, 1 of each color) approximately 7 to 8 mm posterior to the previous sutures (Fig. 1). Alternatively, a penetrating suture grasper such as the Cleverhook or a needle-punch or suture passer (Scorpion, Arthrex, or Expressew II; Mitek) can be used to pass the medial row of sutures. Once this is done, a grasping clamp is used to retrieve 2 limbs of sutures through the anteromedial portal. One anteromedial (blue) limb of suture and 1 posteromedial (violette) limb of suture are tied together. A very simple but solid figure of 8 locking knot (Timber knot) is used to tie the sutures extracorporeally, and the suture is cut short close to the knot

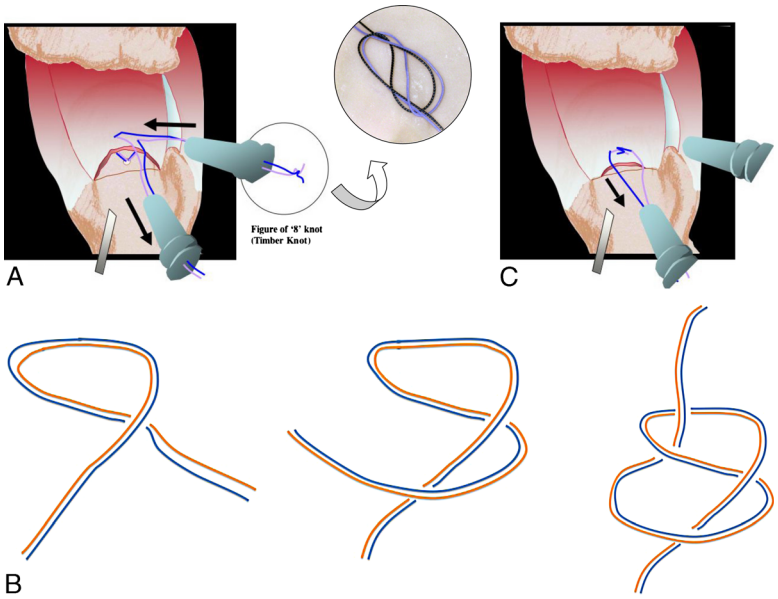

FIGURE 2. One anteromedial (blue) limb of suture and 1 posteromedial (violette) limb of suture are tied together extracorporeally using a figure of 8 locking knot (Timber knot); the Timber knot is a very simple but solid locking, low-profile knot (A). The figure of 8 knot step by step (B). The 2 remaining sutures (of different colors) are then pulled through the anterolateral portal; this creates a mattress suture which fixes the tendon to the medial part of the footprint (C).

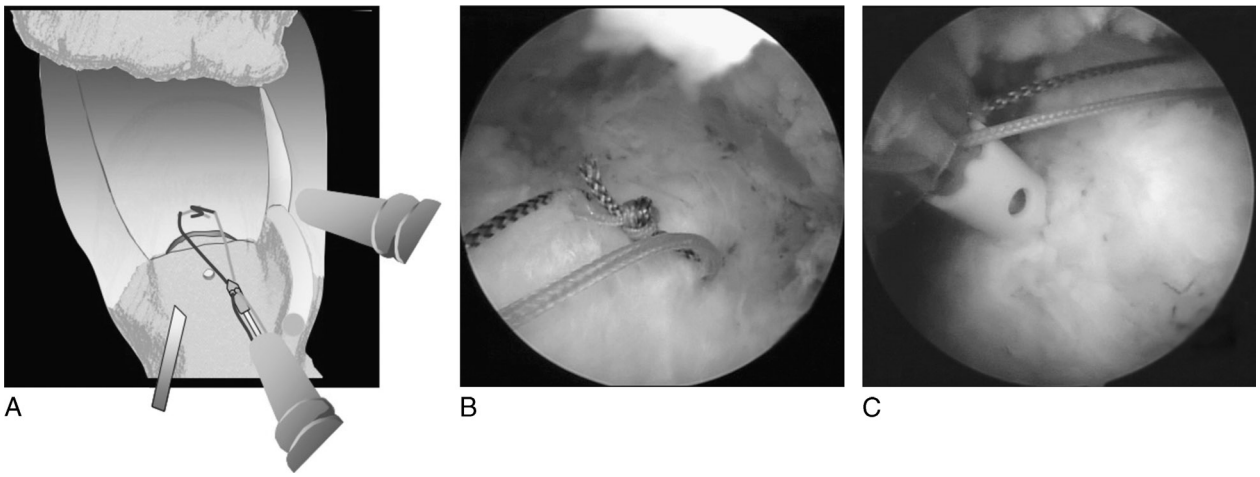

FIGURE 3. The 2 sutures retrieved through the anterolateral portal are shuttled in the eyelet of the second anchor and reintroduced inside the bursa to be placed at the lateral face of the humerus. A, this creates a tension-band configuration (B). Arthroscopic bursal views showing the knotless anchor which is impacted into the lateral cortex of the humerus, approximately 1 to 2 cm from the summit of the greater tuberosity (C).

(Fig. 2). The 2 remaining sutures (of different colors) are then pulled through the anterolateral portal. This creates a mattress suture which fixes the tendon to the medial part of the footprint. Differential traction of each suture limb allows placement of the knot centrally over the anchor. If there is a large or massive tear which necessitates 2 or 3 medial anchors, an identical procedure is repeated more posteriorly.

Step 4: Lateral Row of Sutures

At this stage, an 8-mm threaded cannula (Smith&Nephew) can be inserted into the bursa through the anterolateral portal to facilitate suture and anchor management and to avoid catching some deltoid fibers or fascia with the sutures and anchor. The lateral positions for anchor placement can be marked using electrocautery. The 2 sutures are separated (1 left and 1 right) and passed through the eyelet of an impacted knotless anchor (Versalok; Mitek). The anchor is then passed through the anterolateral cannula and impacted into the lateral cortex of the humerus, approximately 1 to 2 cm from the summit of the greater tuberosity (Fig. 3). The shoulder can be rotated to keep the anchor perpendicular to the lateral cortex. One should avoid twisting the sutures in the cannula when passing the anchor down the cannula.

Using a specialized gun and tensioning wheel, the desired amount of traction is placed on the sutures before they are locked to the anchor. This brings the tendon back onto the lateral part of the footprint and put compression on it (Fig. 4). Once the proper tension is obtained, the anchor is deployed and the sutures are locked using the gun. The trigger on the deployment gun is pulled and this locks the inner sleeve into the outer sleeve of the anchor. The gun and inserter are then removed, and the sutures are cut. No knot has been tied inside the shoulder.

The association of a medial mattress suture and a lateral tension-band suture provide a strong and stiff repair (Fig. 5). Although 2 anchors are sufficient for small rotator cuff tears, for larger tears, the repair is performed using 2 medial anchors and 2 lateral anchors. For massive tears, 3 medial anchors may be placed.

A subacromial decompression with acromioplasty is performed as needed and can be combined with a distal clavicle

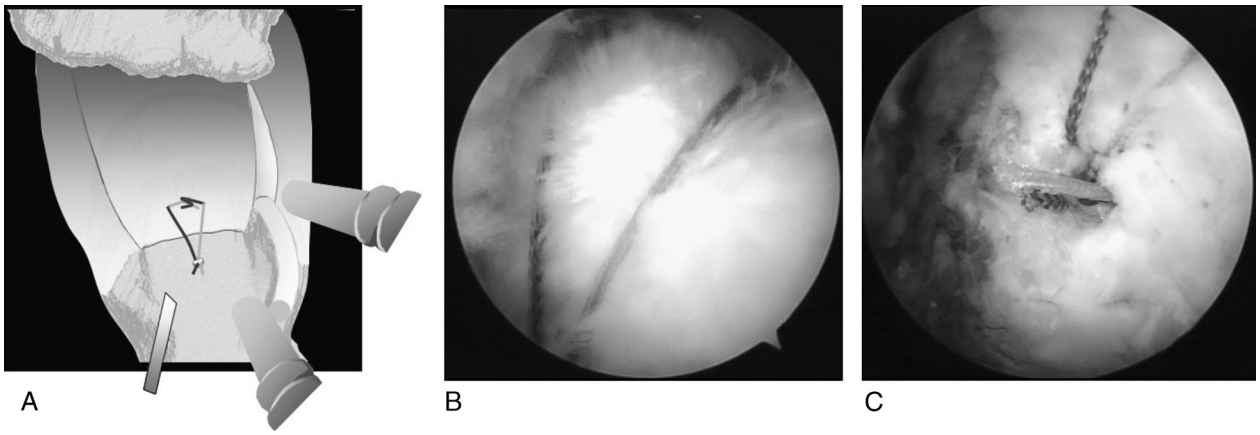

FIGURE 4. The MTB cuff suturing technique provides a strong and stiff repair (A). Arthroscopic bursal views showing the compression of the tendon on the footprint obtained by the tension-band suture configuration (B) and the low placement of the lateral anchor (C).

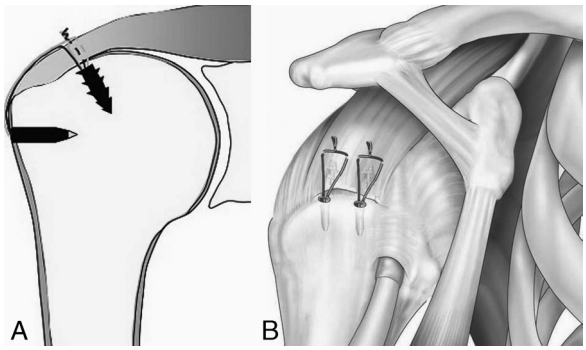

FIGURE 5. The association of a medial mattress suture and a lateral tension-band suture provides a strong and stiff repair (A); for larger tears, the repair is performed using 2 medial anchors and 2 lateral anchors (B).

resection if necessary. A biceps tenotomy or tenodesis can be performed in the presence of a pathological tendon or to avoid its incarceration in the repair.

Postoperatively, the repair is protected with a brace for 3 to 4 weeks. Pendulum exercises commence on the first postoperative day and continue for 3 to 4 weeks. We recommend to our patients that they perform pendulum exercises "5 times a day, for 5 minutes each session" for the first 3 weeks. At 3 weeks, formal physical therapy is begun for continued passive motion exercises in the plane of the scapula. At this stage, hydrotherapy is strongly encouraged; patients stand or sit in a pool, with water level to the clavicle, and they perform passive exercises assisted by counter pressure of water (Archimedes principle). No active motion over the horizontal level is allowed for 6 weeks or until complete recovery of passive motion. Full activity is allowed at 3 months and return to sports is usually allowed between 3 and 6 months.

DISCUSSION

Many arthroscopic double-row rotator cuff repair techniques have already been described to restore the anatomic footprint of the rotator cuff and to add strength and rigidity to the repair.[1–4] However, a good-quality arthroscopic double-row repair can be technically difficult to achieve and time-consuming to perform. Schematically, 3 types of double row (DR) repairs have been described: the "mattress" DR repair,[2] the "double-pulley" DR repair,[1] and the "transosseous-equivalent" DR repair.[4] Our technique is different from all of these techniques, but keeps the main advantages of each of them.

The MTB repair offers the same advantages as our previously described tension-band technique.[8] First, it allows for complete preparation of the cancellous bone bed for tendon healing without the potential compromise of anchor fixation. Second, it provides a large area of contact, almost similar to the original insertion of the supraspinatus. Third, the medial sutures passes take advantage of more healthy tendon for fixation strength. Fourth, the tension-band configuration of the sutures provides compression of the tendon against the footprint, potentially accelerating tendon healing to bone.[9] Lastly, placement of suture anchors in the lateral cortex of the humerus results in a significant increase in the strength of the rotator cuff repair.[10] This is of particular interest in case of osteoporotic greater tuberosity.[6,11]

The MTB technique offers further potential advantages without the complexity associated with other double-row repair techniques. First, there is no need to tie any knot inside the joint; the only knot made is tied extracorporeally. Second, we use a very simple, secure knot for the medial mattress suture (a figure-of-8 or Timber knot) which is a locking knot which cannot slip, thereby improving initial strength and stiffness of the repair. Third, there is minimal risk of knot impingement and wear under the acromial arch because there is no need to tight additional half-hitches. The Timber knot is low profile and is the only knot placed on the superior part of the tendon. Fourth, the medial mattress configuration suture protects the healing zone on the tuberosity from the synovial liquid. Fifth, the lateral tension-band configuration provides compression of the tendon over the footprint which is known to accelerate healing between tendon and bone.[9] Furthermore, the MTB technique, like the transosseous-equivalent technique, is interconnected, as opposed to a double-row technique where the fixation points are separate. From a biomechanical standpoint, it has been shown that the strength of such interconnected repair is maximized by the fact that the load is shared between medial and lateral fixation points.[4]

Finally, the MTB technique is simple to perform (with a short learning curve), quick, and reproducible, thus reducing operative time. Thus far, 70 patients have undergone this new technique at our institution. We have not observed any complications related to suture anchors, infections, or neurological complications. A clinical and anatomical evaluation of the proposed technique is currently under investigation in our Orthopaedic Department.

REFERENCES

1. Arrigoni P, Brady PC, Burkhart SS. The double-pulley technique for double-row rotator cuff repair. *Arthroscopy.* 2007;23:675.el–675.e4.
2. Lo IK, Burkhart SS. Double-row arthroscopic cuff repair: re-establishing the footprint of the rotator cuff. *Arthroscopy.* 2003;19: 1035–1042.
3. Millet PJ, Mazzocca A, Guanche CA. Mattress double anchor footprint repair: a novel, arthroscopic rotator cuff repair technique. *Arthroscopy.* 2004;20(8):875–879.
4. Park MC, ElAttrache NS, Ahmad CS, et al. "Transosseous-equivalent" rotator cuff repair technique. *Arthroscopy.* 2006;22(12):1360.
5. Cole BJ, ElAttrache NS, Anbari A. Arthroscopic rotator cuff repairs: an anatomic and biomechanical rationale for different suture-anchor configurations. Current Concepts. *Arthroscopy.* 2007;23(6):662–669.
6. Nho SJ, Yadav H, Pensak M, et al. Biomechanical fixation in arthroscopic cuff repair. *Arthroscopy.* 2007;23(1):94–102.
7. Boileau P, Brassart N, Watkinson D, et al. Arthroscopic repair of full-thickness tears of the supraspinatus: does the tendon really heal? *J Bone Joint Surg Am*. 2005;87:1229–1240.
8. Boileau P, Chuinard C, Brassart N, et al. The tension-band suture technique for arthroscopic rotator cuff repair. *Tech Shoulder Elbow Surg*. 2007;8(1):47–52.
9. Weiler A, Hoffmann RFG, Bail HJ, et al. Tendon healing in a bone tunnel. Part II: Histologic analysis after biodegradable interference fit fixation in a model of anterior cruciate ligament reconstruction in sheep. *Arthroscopy.* 2002;18:124–135.
10. Rossouw DJ, McElroy BJ, Amis AA, et al. A biomechanical evaluation of suture anchors in repair of the rotator cuff. *J Bone Joint Surg Br.* 1997;79(3):458–461.
11. Meyer DC, Fucentes SF, Koller B, et al. Association of osteopenia of the humeral head with full-thickness rotator cuff tears. *J Shoulder Elbow Surg*. 2004;13(3):333–337.

