

# The Injured Shoulder in High-Level Male Gymnasts, Part 1

## Epidemiology and Pathoanatomy of Surgically Treated Lesions

Patrick Gendre,\* MD, and Pascal Boileau,<sup>†‡</sup> MD, PhD

*Investigation performed at the University Institute for Locomotion and Sports, University of Côte d'Azur, Nice, France*

**Background:** Weightbearing and traction-suspension movements with the upper limbs put considerable demands upon the shoulder region of high-level gymnasts. The diagnosis of instability in these gymnasts may be difficult because voluntary inferior shoulder subluxation is part of their training and is needed to perform some acrobatic figures.

**Purpose:** To (1) assess the epidemiology of shoulder lesions requiring surgery, (2) describe the types of injuries and assess which maneuvers and equipment put the gymnast most at risk, and (3) present a pathoanatomic classification of the injured shoulder in high-level male gymnasts.

**Study Design:** Case series; Level of evidence, 4.

**Methods:** Over a 20-year period (1994-2014), 26 high-level male gymnasts (30 shoulders; mean age, 22 years; range, 16-33 years) were referred to our surgical center for shoulder pain or instability. Four gymnasts underwent surgery on both shoulders. All shoulders were evaluated clinically, radiologically, and arthroscopically. An independent observer evaluated the circumstances in which these lesions occurred, including the apparatus used and the maneuvers performed.

**Results:** The mean duration of symptoms before surgery was 8 months (range, 6-24 months). Eighteen injured shoulders (60%) had chronic overuse injuries. In 27 shoulders (90%), the mechanism of injury was traction of the arm in forced flexion-rotation while using suspension equipment with locked hands on the bars or the rings. In the remaining 3 shoulders, the traumatic position was one of an isometric muscle contraction against gravity, sustained while performing strength-and-hold positions on the rings. Based on the main presenting symptoms (pain and/or instability) and main anatomic lesions found during arthroscopy, the injured gymnasts' shoulders were classified into 2 categories: painful shoulders (n = 13) with no clinical, radiological, or arthroscopic findings of instability (mainly superior cuff and biceps anchor lesions) and unstable shoulders (n = 17) with isolated inferior capsule labral tears or mixed lesions (tendinous and capsulolabral). Some gymnasts with inferior labral tears had no recall of having suffered a dislocation or subluxation.

**Conclusion:** The majority of injuries requiring surgery in this population occurred during traction in forced flexion-rotation using suspension equipment. Injured shoulders were classified as either painful or unstable shoulders.

**Keywords:** high-level gymnasts; shoulder injury; instability; labral tears; SLAP lesions; partial cuff tears; shoulder arthroscopy

Artistic gymnastics is one of different competitive disciplines regulated internationally by the International Gymnastics Federation (Fédération Internationale de Gymnastique; Lausanne, Switzerland).<sup>15</sup> Many shoulder injuries are seen because several complex movement patterns with extreme joint positions are common to acrobatic sequences, strength-and-hold positions, and choreographic and artistic movements. Male artistic gymnasts perform 6 routines: 3

using suspension apparatus (the rings, the parallel bars, and the horizontal bar) and 3 using support apparatus (floor exercises, the pommel horse, and the vaulting table). Weightbearing movements with the upper limbs in men's artistic gymnastics (either in hanging positions or arm support positions) put considerable demands on the shoulder region.

During gymnastics, the shoulder is often the site of overuse injuries owing to the repetition of technical movements or acute trauma during violent movements or intense muscle contractions.<sup>9,13,26,32</sup> In 1993, Dixon and Fricker<sup>14</sup> demonstrated 2.5-times more chronic and 1.5-times more acute

The Orthopaedic Journal of Sports Medicine, 9(10), 23259671211043449

DOI: 10.1177/23259671211043449

© The Author(s) 2021

This open-access article is published and distributed under the Creative Commons Attribution - NonCommercial - No Derivatives License (<https://creativecommons.org/licenses/by-nc-nd/4.0/>), which permits the noncommercial use, distribution, and reproduction of the article in any medium, provided the original author and source are credited. You may not alter, transform, or build upon this article without the permission of the Author(s). For article reuse guidelines, please visit SAGE's website at <http://www.sagepub.com/journals-permissions>.

injuries of the upper limbs in male gymnasts than female gymnasts. In a 2005 review of the literature, Caine and Nasar<sup>7</sup> showed that in female artistic gymnasts, upper limb injuries made up 12.8% to 36% of all injuries and shoulder injuries made up 0% to 4.2%. In male gymnasts, upper limb injuries are more frequent, ranging from 36% to 54% of all injuries, and often involve the shoulders (up to 19% of all injuries).<sup>7</sup> These injuries occur particularly during overtraining periods before or during competition and have been attributed to a high level of physical and psychological stress.<sup>19,27,29</sup> Shoulder injuries are well described in overhead athletes and swimmers,<sup>6,22,23,25,28,31</sup> but the current literature about gymnasts' shoulders is scarce and concentrates on the biomechanics of gymnastic movements.<sup>1,2,3,10,20,24</sup>

This was a 2-part study. The objectives of part 1 were (1) to assess the surgical epidemiology of high-level gymnasts' shoulder lesions, (2) to describe the type of injuries seen and assess which maneuvers and equipment put the gymnast most at risk, and (3) to present a pathoanatomic classification of the gymnast's shoulder. In part 2,<sup>17</sup> we evaluated the results of shoulder surgery in these gymnasts.

## METHODS

### Study Design

This was a descriptive epidemiological and anatomic study of a consecutive series of high-level male artistic gymnasts referred and surgically treated over a 20-year period (1994-2014). The study was approved by the local ethics committee. Inclusion criteria included (1) gymnasts actively competing at the regional level or above with a training regime in excess of 12 h/wk, (2) shoulder injuries sustained during gymnastics (either acute traumatic or overuse injuries), and (3) shoulder injuries requiring arthroscopic or surgical treatment.

### Assessment of Shoulder Symptoms and Pathology

A single experienced shoulder surgeon performed all initial clinical, radiological, and arthroscopic diagnoses. At the first visit, all patients had a standardized physical bilateral and comparative examination, including the rotator cuff and long head of the biceps, hyperlaxity and instability testing, and radiographs (anteroposterior, lateral, and axillary views). Before surgery, additional imaging studies were performed in all cases with magnetic resonance imaging (MRI), MRI arthrogram, or computed tomography arthrogram.

Shoulder arthroscopy was performed in the beach-chair position. The arm was placed in a mobile gutter support without traction, allowing the surgeon to perform dynamic exploration of the shoulder by mobilizing the upper limb. Evaluation was performed to document the amount of glenohumeral translation, the presence of labral tears (Bankart or SLAP [superior labral anterior and posterior] lesion), lesions of the long head of the biceps, partial- or full-thickness rotator cuff tears, as well as bony lesions (glenoid fractures or Hill-Sachs lesions). A probe was used to evaluate the extent of labral detachment or "crack" around the glenoid, the degree of capsular laxity, and the quality of the tissue. The glenoid rim was divided into 6 regions, as previously described,<sup>4</sup> to denote the location of injury (Figure 1). A labral detachment located in the lower half (zone C, D, or E in Figure 1) was considered to be associated with shoulder instability.<sup>4</sup>

### Assessment of the Mechanism of Injury

Retrospective assessment of the mechanism of injury was made by an independent observer, himself a former high-level gymnast and a practicing orthopaedic surgeon. All patients underwent physical evaluation, and a standardized interview was done: (1) the mechanism and chronicity of injury (traumatic or overuse), (2) the apparatus involved, and (3) the specific exercise involved in the injury as well as the traumatic moment during the realization of this exercise. This allowed deduction of the position and rotation of the upper limb and shoulder at the time of trauma, as well as the state of muscle contraction.

## RESULTS

### Epidemiology

Over the 20-year study period, 26 high-level male gymnasts (30 shoulders) were referred by the medical team (rehabilitation specialists, sports physicians, and coaches) of the national gymnastics training center in Antibes, France, to the senior shoulder surgeon for symptoms precluding training and competition. Four gymnasts underwent surgery on both shoulders.

The mean age at surgery was 22 years (range, 16-33 years). At the time of surgery, of the 26 high-level male gymnasts, 7 competed at the international level, 15 at the national elite level, and 4 at the regional level. The mean weekly training regime was 22.5 hours (range, 12-30 hours). All gymnasts performed all routines. The mean duration of symptoms before surgery was 8 months (range, 6-24 months).

†Address correspondence to Pascal Boileau, MD, PhD, Institut de Chirurgie Réparatrice, 7 Avenue Durante, 06000 Nice, France (email: pr.boileau@icr-nice.com).

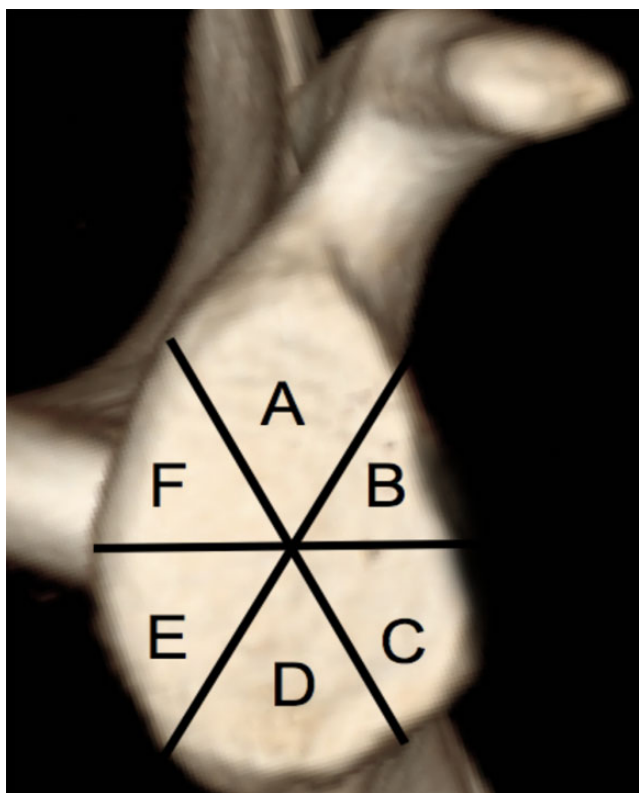
\*Polyclinique Saint Jean, Cagnes-sur-Mer, France.

†Institut de Chirurgie Réparatrice, Nice, France.

Final revision submitted April 29, 2021; accepted May 13, 2021.

One or more of the authors has declared the following potential conflict of interest or source of funding: P.B. has received consulting fees from Smith & Nephew and royalties from Tornier/Wright. AOSSM checks author disclosures against the Open Payments Database (OPD). AOSSM has not conducted an independent investigation on the OPD and disclaims any liability or responsibility relating thereto.

Ethical approval for this study was obtained from the University Institute for Locomotion and Sports (2016-03).



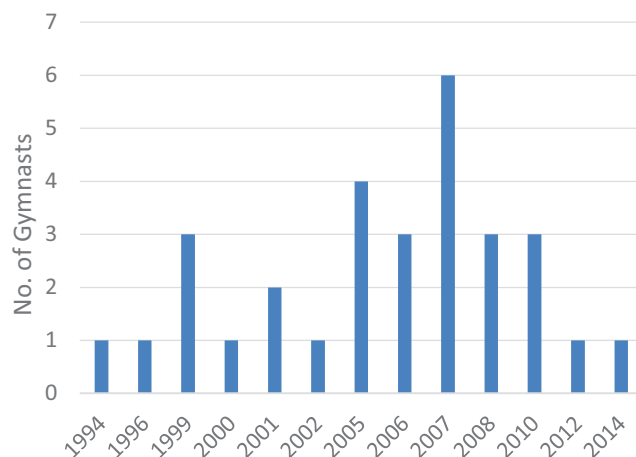
**Figure 1.** Labral attachment was divided into 6 zones (A-F). Labrum not attached in zone B was considered physiologic. Labral tears located below the equator (zones C-E) were considered secondary to inferior traumatic instability. Labral tears in zone A were diagnosed as SLAP (superior labral anterior and posterior) lesions. Labral tears in zone A or F associated with deep rotator cuff tears (“kissing lesions”) were diagnosed as posterosuperior impingement.

Figure 2 shows the number of gymnasts who underwent surgery per year. Before surgery, 25% of patients had  $\geq 1$  corticosteroid injection to the shoulder, and 60% had undergone a specific rehabilitation program for at least 3 months. Three gymnasts had previous arthroscopic surgery at another center, with the diagnosis of type 2 SLAP lesion,<sup>33</sup> and had persistent pain during gymnastics after SLAP repair at 2 years.

### Presenting Symptoms

The support arm (weightbearing arm when the gymnast moves with 1 arm) was involved in 19 cases (63%). In 21 injured shoulders (70%), pain was the presenting symptom, precluding training and competition. In the 9 other injured shoulders, instability was the presenting symptom (1 dislocation and 8 subluxations); the apprehension-relocation test result was positive in 7 cases and the jerk test was positive in 2 cases.

Eighteen injured shoulders (60%) had chronic overuse injuries. In 12 shoulders, an isolated acute traumatic event was found.



**Figure 2.** Number of gymnasts who underwent surgery per year.

### Apparatus, Exercises, and Traumatic Positions

In 27 shoulders (90%), the mechanism of injury was traction in forced flexion-rotation when using suspension equipment with “locked hands” on the bars or rings: 16 in forced flexion–internal rotation (Figure 3A) and 11 in forced flexion–external rotation. Twelve shoulder injuries were sustained on the rings, 9 on the horizontal bar, and 6 on the parallel bars. In the remaining 3 shoulders, the traumatic position was one of an isometric muscle contraction against gravity, sustained while performing strength-and-hold positions on the rings (Figure 3B). No gymnasts had any trauma during a fall to the ground from an apparatus.

### Pathoanatomic Classification of the Gymnast’s Shoulder

In 18 shoulders, an isolated capsuloligamentous or tendinous lesion was found, whereas in 12 shoulders (40%), several lesions were associated.

Although several lesions could be associated in the same patient, we classified the injured gymnast’s shoulder into 2 groups according to the dominant pathology found at arthroscopy and the presented symptoms: painful shoulders and unstable shoulders (Table 1).

**Painful Shoulder Group.** Thirteen shoulders demonstrated no history of instability and no inferior labral tears. In this group, patients were diagnosed with posterosuperior glenoid impingement and glenohumeral internal rotation deficit<sup>30,35</sup> ( $n = 3$ ), articular-sided supraspinatus tear ( $n = 5$ ), and superior labral tears, including SLAP lesions ( $n = 5$ ) (Figure 4A).

**Unstable Shoulder Group.** Seventeen shoulders showed a history or lesion of instability, including 1 isolated traumatic dislocation and 8 isolated subluxations. In the other 8 cases, there were obvious anatomic lesions of instability, with excessive glenohumeral translation during arthroscopy ( $>75\%$ ), although the gymnasts could not recall any clear shoulder dislocation or subluxation events.<sup>5</sup>



**Figure 3.** Two traumatic exercises in men's gymnastics. (A) Forced flexion–internal rotation of the shoulder during parallel bars exercise in suspension. (B) Isometric muscle contraction against gravity during a strength-and-hold element on rings (the “iron cross”).

TABLE 1

Classification of Shoulders Into 2 Groups According to the Presenting Symptoms and Dominant Anatomic Lesions Found at Arthroscopy<sup>a</sup>

	Capsulolabral Tear Location (No.) <sup>b</sup>	Tendinous Tear	Associated Lesion
Painful shoulder group (n = 13)			
PSGI (n = 3)	Zone A-F (3)	Partial-thickness SP tear (3)	—
SP tear (n = 5)	—	Articular-sided SP tear (5)	LHB delamination (1) Horizontal instability LHB (2)
LHB lesions (n = 5)	Zone A (5)	Isolated type 2 SLAP lesion	—
Unstable shoulders group (n = 17)	Zone A and CD (4) Zone CDE (3) Zone CD (3) Zone C (2) Zone A-E (1) Zone DE (1) Isolated inferior capsule tear (3)	—	Type 2 SLAP lesion (4) Type 4 SLAP lesion (1) Subluxation LHB (1) Articular-sided SP tear (3)

<sup>a</sup>LHB, long head of the biceps; MT, musculotendinous; PSGI, posterosuperior glenoid impingement; SLAP, superior labral anterior and posterior; SP, supraspinatus.

<sup>b</sup>See Figure 1 for definition of zones.

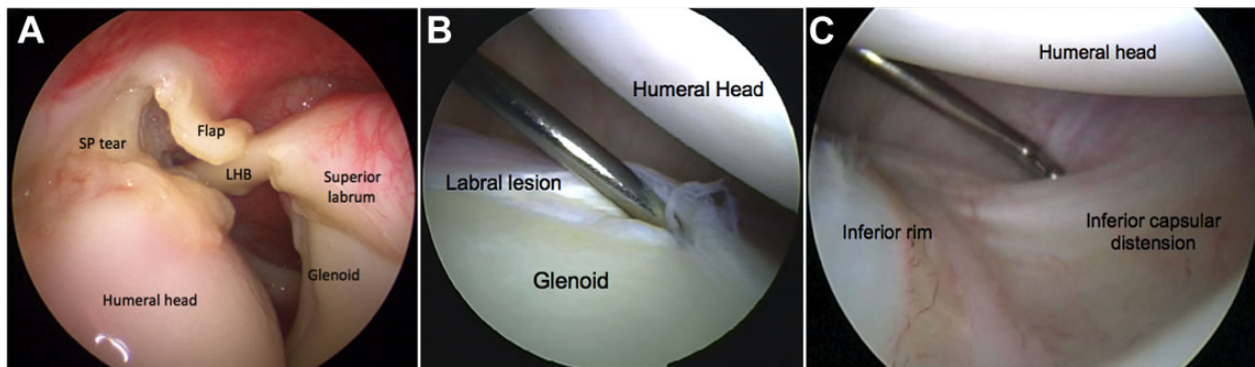
Anatomic lesions of instability were capsulolabral tears in zone C, D, or E (n = 14), inferior capsular tear (n = 3), Hill-Sachs lesions (n = 4), and glenoid fracture (n = 1) (Figure 4, B and C).

## DISCUSSION

The study shows that shoulder injuries requiring surgery in high-level gymnasts occurred mainly in young athletes when the gymnast performs high kinetic exercises with suspensory equipment. The gymnasts' shoulder pathology was predominantly one of overuse injury.

The main mechanism of injury was forced flexion with locked hands on the bars or rings. The high tensile forces on the upper limbs (up to 6- to 8.5-times body weight) and the very low muscle activity around the shoulder in suspension exercises can account for the observed injuries (labral tears, biceps or cuff tears) when using this equipment.<sup>10,20,24</sup>

We saw more shoulder injuries between 2005 and 2008. Modifications to the system used to score competitive gymnastics, which was introduced by the International Gymnastics Federation between 2004 and 2008, appear to have had an impact on the incidence of shoulder lesions seen in this sample. The code of points is the scoring system used to



**Figure 4.** Posterior arthroscopic views demonstrate some of the pathologies found in the 2 categories of gymnasts' shoulders. (A) Left shoulder shows an articular-sided supraspinatus tear with a flap of the tendon and lateral instability of the biceps tendon in a gymnast with chronic shoulder pain (painful shoulder group). (B, C) Right shoulder shows an abnormal capsular distension with a "labral crack" in zones C and D in a gymnast with chronic shoulder pain and no recall of any subluxation. LHB, long head of the biceps; SP, supraspinatus.

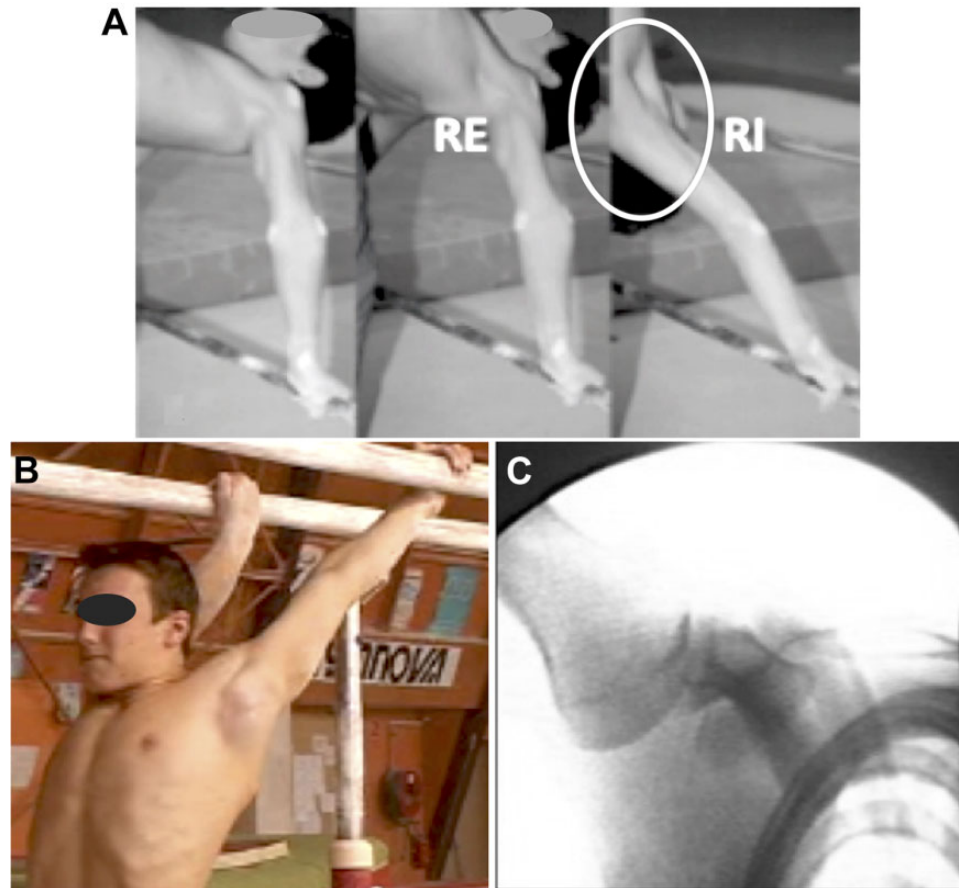
provide an objective means of evaluating gymnastic exercises at all competitive levels.<sup>15</sup> Since 2005, gymnasts obtain higher points by performing more difficult and repeated combination exercises. The repetition of combined exercises may result in poor control of humeral head positioning and cause capsulolabral, tendinous, and articular damage.

Based on the presenting symptoms and main anatomic lesions found during arthroscopy, we divided the injured gymnasts' shoulders into 2 categories. We termed the first category *painful shoulders*, since pain was the main symptom and was associated with partial rotator cuff tears, biceps pathology, or superior labral tears, including SLAP lesions (13 shoulders). We termed the second category *unstable shoulders* since the gymnasts presented with shoulder dislocations or subluxations (9 shoulders) that were clearly identified by the athletes and that correlated with anteroinferior or posteroinferior capsulolabral tears and/or bony lesions. We also included 7 shoulders in the second group in which the gymnasts had specified only shoulder pain, since inferior labral tears or capsular stretching was found during arthroscopy.<sup>5</sup> Although none of these 7 gymnasts could recall any episodes of subluxation or dislocation, we considered the capsulolabral lesions as witnesses of unrecognized traumatic inferior shoulder subluxations. The crack in the labrum gives the direction of the instability (antero- or posteroinferior). Although concomitant anatomic lesions can be present in this second group, this classification is important because it has direct consequences on the diagnosis and possible surgical treatment of the injured gymnast's shoulder.

From a diagnostic standpoint, one should understand that gymnasts do not always perceive symptoms of shoulder instability (ie, subluxations). It is important for surgeons, sports doctors, and physical therapists to understand a physiological specificity of the gymnast's shoulder: the need for all gymnasts to perform inferior shoulder stretching. This maneuver, which is part of their training, is needed to allow the passage from extension and internal rotation to flexion and external rotation when the

hand is locked on the bars during a figure (Figure 5). To be able to perform what they call "shoulder dislocations," gymnasts spend part of their training stretching the inferior capsule, since their youngest age. As a result, gymnasts consider inferior laxity of the shoulder a kind of "normal," and they do not always realize that the shoulder may become involuntary unstable. One could consider this movement to be part of the Codman paradox,<sup>11</sup> which allows going from flexion and external rotation to extension and internal rotation, or vice versa. This acquired inferior laxity allows the gymnast "to put the ball outside the socket" without creating any lesion or symptoms. However, the fact that gymnasts present with such inferior laxity does not prevent them from having additional trauma, which can then cause pain and/or instability symptoms. This possibly explains why the gymnasts' shoulders predominantly dislocated in an inferior direction: 11 of 14 labral lesions were to the inferior glenoid rim (region D) and were simple labral fissures (labral cracks).

Arthroscopic assessment of glenohumeral translation is difficult and not very meaningful in the gymnast's shoulder. While in a "normal" person, glenohumeral translation >50% can be considered pathological,<sup>4</sup> in the high-level gymnast, inferior glenohumeral translation of almost 100% can be considered normal or physiological. Differentiating between the normal morphology of the gymnast's shoulder and capsular pathology can be problematic. According to authors such as Glousman and Bird,<sup>18</sup> Kvitne and Jobe,<sup>22</sup> and Jobe et al,<sup>21</sup> instabilities without previous dislocation or subluxation may be secondary to progressive stretching of the capsule by overuse and/or muscle imbalance in overhead athletes. This theory also appears valid for gymnasts. We found isolated abnormal capsular distension in 3 shoulders (without a labral lesion and/or a bony lesion), with suspected microscopic capsular tears of the inferior capsule and inferior glenohumeral ligament. Gannon and Bird<sup>16</sup> suggested that greater passive range of movement in gymnasts and dancers is partly inherited and partly acquired. Capsular distension may occur from repetitive overuse and training.



**Figure 5.** Physiologic specifics of the gymnast's shoulder: voluntary inferior shoulder subluxation is needed to allow complete rotation of the shoulder while the hand and wrists are locked on the bars or rings. (A) In this exercise on the horizontal bar, the gymnast who has his shoulder in extension and external rotation (RE) makes an effort to internally rotate (RI) and dislocate his shoulder inferiorly. (B) Extension and internal rotation during the “voluntary gymnast shoulder inferior subluxation.” (C) Fluoroscopic image demonstrates the inferior glenohumeral subluxation of the humeral head during the “dislocation maneuver.”

Finally, bony lesions are relatively infrequent in the gymnast's unstable shoulder: in the present series, a single glenoid fracture and 4 Hill-Sachs lesions were identified. In the literature,<sup>4,8,12</sup> the frequency of these lesions in unstable shoulders is much higher, up to 80%. This finding is understandable, since inferior capsular laxity is a normal feature of gymnasts' shoulders. Nevertheless, we recommend performing MRI or computed tomography imaging with 3-dimensional reconstruction to detect unrecognized glenoid bone defects.<sup>34</sup>

From the observations, we identified 40% of shoulders requiring surgery with associated capsulolabral and tendinous lesions. Facing a painful shoulder in a high-level gymnast, the sports medicine specialist must (1) elicit a thorough instability history and perform a physical examination for instability; (2) understand the mechanism of injury, bearing in mind the apparatus used; (3) look for inferior capsulolabral lesions on imaging and at arthroscopy; and (4) not be blinded by associated lesions (eg, SLAP or rotator cuff lesions).

This study has several limitations. It was a retrospective single-center study, and the mechanism was inferred from

athletes' recall of the injury. It reflects only the epidemiology of lesions referred to a surgical unit and does not represent those shoulder injuries that responded to nonoperative measures. We also did not analyze glenoid version as a potential risk factor. A multicenter study examining high-level gymnasts' shoulder injuries treated medically and surgically would be necessary for a more complete understanding of the epidemiology of shoulder injuries in this group of athletes. Nevertheless, the study has several strengths: (1) a relatively large patient sample, which gives a good representation of shoulder injuries in high-level male gymnasts; (2) a homogenous group of patients (young high-level gymnasts); (3) radiological and arthroscopic evaluation of anatomic lesions by a shoulder specialist; and (4) evaluation of the mechanism of injuries by an experienced orthopaedic surgeon, himself a former high-level gymnast.

## CONCLUSION

Gymnasts' shoulder injuries were more commonly seen in young gymnasts. They occurred mainly during traction in

forced flexion-rotation using suspension equipment with locked hands on the bars or rings and high kinetic movements. The superior and articular-surface rotator cuff, the SLAP complex/labrum, and the long head of biceps were especially affected. Although inferior labral tears were frequent, the diagnosis of instability may be difficult since gymnasts often underestimate instability symptoms because “voluntary inferior shoulder dislocation” is part of their training and exercises. Arthroscopy is a useful tool to help diagnose lesions of the gymnast’s shoulder. Based on the main presenting symptoms and anatomic lesions found during arthroscopy, gymnasts’ shoulders can be divided into 2 categories: (1) painful shoulders with mainly superior cuff and biceps anchor lesions and (2) unstable shoulders with isolated inferior capsule labral tears or mixed lesions (tendinous and capsulolabral).

## ACKNOWLEDGMENT

The authors thank Laury Païdassi, MD, Philippe Oddoux, and Luc d’Asnières de Veigy for their help with the management of high-level gymnasts and Robert Houghton-Clemmey for his help with English writing and translation.

## REFERENCES

- Aronen JG. Problems of the upper extremity in gymnastics. *Clin Sports Med*. 1985;4(1):61-71.
- Bernasconi S, Tordi N, Parratte B, Rouillon JD, Monnier G. Surface electromyography of nine shoulder muscles in two iron cross conditions in gymnastics. *J Sports Med Phys Fitness*. 2004;44(3):240-245.
- Bernasconi SM, Tordi NR, Parratte BM, Rouillon JD. Can shoulder muscle coordination during the support scale at ring height be replicated during training exercises in gymnastics? *J Strength Cond Res*. 2009;23(8):2381-2388.
- Boileau P, Lafosse L. Évaluation arthroscopique et prospective des lésions d’instabilité antérieure chronique de l’épaule. In: *Perspectives en arthroscopie*. Springer Verlag; 2002:194-196.
- Boileau P, Zumstein M, Balg F, Penington S, Bicknell RT. The unstable painful shoulder (UPS) as a cause of pain from unrecognized antero-inferior instability in the young athlete. *J Shoulder Elbow Surg*. 2011;20(1):98-106.
- Burkhart SS, Morgan CD, Kibler WB. Shoulder injuries in overhead athletes: the “dead arm” revisited. *Clin Sports Med*. 2000;19:125-158.
- Caine DJ, Nassar L. Gymnastics injuries. *Med Sport Sci*. 2005;48:18-58.
- Calandra JJ, Baker CL, Uribe J. The incidence of Hill-Sachs lesions in initial anterior shoulder dislocations. *Arthroscopy*. 1989;5(4):254-257.
- Caplan J, Julien TP, Michelson J, Neviasser RJ. Multidirectional instability of the shoulder in elite female gymnasts. *Am J Orthop*. 2007;36(12):660-665.
- Caraffa A, Cerulli G, Rizzo A, Buompadre V, Appoggetti S, Fortuna M. An arthroscopic and electromyographic study of painful shoulders in elite gymnasts. *Knee Surg Sports Traumatol Arthrosc*. 1996;4(1):39-42.
- Codman EA. *The Shoulder: Rupture of the Supraspinatus Tendon and Other Lesions in or About the Subacromial Bursa*. Thomas Todd; 1934.
- Coudane H, Walch G. L’instabilité antérieure chronique de l’épaule chez l’adulte. Symposium de la Sofcot. Paris, 1999. *Rev Chir Orthop Reparatrice Appar Mot*. 2000;86(suppl\_1):91-150.
- De Carli A, Mossa L, Larciprete M, Ferretti M, Argento G, Ferretti A. The gymnast’s shoulder MRI and clinical findings. *J Sports Med Phys Fitness*. 2012;52(1):71-79.
- Dixon M, Fricker P. Injuries to elite gymnasts over 10 yr. *Med Sci Sports Exerc*. 1993;25:1322-1329.
- Fédération Internationale de Gymnastique. *Code of Points: Men’s Artistic Gymnastics*. Fédération Internationale de Gymnastique; 2009.
- Gannon LM, Bird HA. The quantification of joint laxity in dancers and gymnasts. *J Sports Sci*. 1999;17(9):743-750.
- Gendre P, Boileau P. The injured shoulder in high-level male gymnasts, part 2: can athletes return to competition after surgery? *Orthop J Sports Med*. 2021;9(10). doi:10.1177/23259671211043468
- Glousman R, Jobe F, Tibone J, Moynes D, Antonelli D, Perry J. Dynamic electromyographic analysis of the throwing shoulder with glenohumeral instability. *J Bone Joint Surg Am*. 1988;70(2):220-226.
- Graption X, Lion A, Gauchard GC, et al. Specific injuries induced by the practice of trampoline, tumbling and acrobatic gymnastics. *Knee Surg Sports Traumatol Arthrosc*. 2012;21:494-499.
- Holvoet P, Lacouture P, Duboy J, Junqua A, Bessonnet G. Joint forces and moments involved in giant swings on the high bar. *Sci Sports*. 2002;17(1):26-30.
- Jobe FW, Giangarra CE, Kvitne RS, Glousman RE. Anterior capsulolabral reconstruction of the shoulder in athletes in overhand sports. *Am J Sports Med*. 1991;19(5):428-434.
- Kvitne RS, Jobe FW. The diagnosis and treatment of anterior instability in the throwing athlete. *Clin Orthop Relat Res*. 1993;291:107-123.
- Limpisvasti O, ElAttrache NS, Jobe FW. Understanding shoulder and elbow injuries in baseball. *J Am Acad Orthop Surg*. 2007;15(3):139-147.
- Mark A, Brewin MRY, David GK. Minimising peak forces at the shoulders during backward longswings on rings. *Human Movement Science*. 2000;19(5):717-736.
- Mazoue CG, Andrews JR. Repair of full-thickness rotator cuff tears in professional baseball players. *Am J Sports Med*. 2006;34(2):182-189.
- Meeusen R, Borms J. Gymnastic injuries. *Sports Med*. 1992;13:337-356.
- Pettrone FA, Ricciardelli E. Gymnastic injuries: the Virginia experience 1982-1983. *Am J Sports Med*. 1987;15:59-62.
- Rupp S, Berninger K, Hopf T. Shoulder problems in high level swimmers—impingement, anterior instability, muscular imbalance? *Int J Sports Med*. 1995;16(8):557-562.
- Sands WA, Shultz BB, Newman AP. Women’s gymnastics injuries: a 5-year study. *Am J Sports Med*. 1993;21:271-276.
- Scheibel M. The gymnast shoulder: prevalence of structural lesions and injury patterns. In: Boileau P, ed. *Shoulder Concepts*. Sauramps Medical; 2016
- Shanley E, Rauh MJ, Michener LA, Ellenbecker TS, Garrison JC, Thigpen CA. Shoulder range of motion measures as risk factors for shoulder and elbow injuries in high school softball and baseball players. *Am J Sports Med*. 2011;39(9):1997-2006.
- Silvij S, Nocini S. Clinical and radiological aspects of gymnast’s shoulder. *J Sports Med Phys Fitness*. 1982;22:49-53.
- Snyder SJ, Karzel RP, Del Pizzo W, Ferkel RD, Friedman MJ. SLAP lesions of the shoulder. *Arthroscopy*. 1990;6(4):274-279.
- Sugaya H, Moriishi J, Dohi M, Kon Y, Tsuchiya A. Glenoid rim morphology in recurrent anterior glenohumeral instability. *J Bone Joint Surg Am*. 2003;85(5):878-884.
- Walch G, Liotard JP, Boileau P, Noel E. Postero-superior glenoid impingement. Another shoulder impingement. Article in French. *Rev Chir Orthop Reparatrice Appar Mot*. 1991;77(8):571-574.