

# Anatomical and reverse shoulder replacement with a convertible, uncemented short-stem shoulder prosthesis: first clinical and radiological results

Marc Schnetzke<sup>1</sup>  · Alexander Preis<sup>2</sup> · Sebastian Coda<sup>3</sup> · Patric Raiss<sup>4</sup> · Markus Loew<sup>2</sup>

Received: 7 July 2016  
© Springer-Verlag Berlin Heidelberg 2017

**Keywords** Short stem · Shoulder arthroplasty · Stress shielding · Radiolucent lines · Metaphyseal fixation

## Introduction

Standard humeral long stems are associated with complications such as operative humeral fractures, stress shielding, aseptic loosening and traumatic periprosthetic fractures [1, 2, 7, 30]. Revision of both cemented and uncemented long humeral stems is challenging due to stem extraction and potential bone loss [23]. Therefore, preservation of bone has become a major concern in total shoulder replacement surgery [9].

Consequently, investigations on humeral stem design have focused on two main issues: shortening of the stem and development of a convertible modular humeral platform system [11, 29]. Shortening of the humeral stem with metaphyseal fixation aims to preserve bone stock, decrease the rate of stress shielding, eliminate the diaphyseal stress riser and facilitate stem removal in the event of revision [16, 21, 22, 26].

Recently, this study group published the first clinical and radiological follow-up of a non-convertible anatomic

short-stem shoulder prosthesis (Ascend™ Monolithic; Tornier Inc. ®) [24, 25]. In the short term, the clinical results for different indications including primary and secondary osteoarthritis and rheumatoid arthritis were comparable to those of third- and fourth-generation standard stem arthroplasty [4, 10, 14]. X-ray analysis had proven a relatively high rate of bony adaptations after minimum of 2-year follow-up [24]. The prosthetic design has subsequently been modified: a circumferential porous coating at the metaphyseal part of the stem has been added as an attempt to improve proximal humeral fixation and a convertible humeral platform system has been established. The purpose of the present study was to review the clinical and radiological results of shoulder replacement surgery with this new short-stem prosthesis system.

## Materials and methods

This prospective study was conducted with the approval of the local ethics committee (ATOS no. 8/15). Between October 2012 and December 2013, 57 patients underwent primary prosthetic shoulder replacement with the Tornier Aequalis Ascend™ Flex Shoulder System (Fa. Wright, Memphis, Tennessee, USA). Thirty-two patients underwent anatomical total shoulder replacement (TSR) with a cemented keeled glenoid (Aequalis Glenoid) and 25 patients were treated by means of primary reverse total shoulder replacement (rTSR) with a reversed glenoid (Aequalis Reversed II). All operations were performed by the senior author (M.L.).

Three patients (5.3%) were lost to follow-up and one patient (1.8%) died of unrelated causes. Twenty-nine of 32 patients (90.6%) with TSR and 24 of 25 patients (96%)

✉ Marc Schnetzke  
marcschnetzke@gmx.de

<sup>1</sup> BG Trauma Center Ludwigshafen at the University of Heidelberg, Ludwig-Guttman-Straße 13, Ludwigshafen on the Rhine 67071, Germany

<sup>2</sup> ATOS Clinic Heidelberg, German Joint Center, Shoulder and Elbow Surgery, Heidelberg, Germany

<sup>3</sup> Hospital Dipreca, Santiago, Chile

<sup>4</sup> OCM Klinik München, München, Germany

with rTSR could be included in this study. The mean duration of follow-up was 25 months (range 20–35).

In the TSR group, none of the patients had bilateral procedures. The indication for TSR was primary osteoarthritis in 18 patients (62.1%), sequelae of trauma in eight patients (27.6%), ischaemic head necrosis in two patients (6.9%) and rheumatoid arthritis in one patient (3.4%). Mean age was 63 years (38 to 79). Seventeen patients (58.6%) were female and 12 were male (41.4%). The right shoulder was operated in 16 patients (55.2%) and the dominant side in 15 patients (51.7%).

In the rTSR group, one patient had a bilateral procedure. The indication for rTSR was cuff-tear arthropathy in 17 shoulders (70.8%), posttraumatic sequelae in five shoulders (20.8%) and primary osteoarthritis in two shoulders (8.3%). Twenty patients (83.3%) were female and four were male (16.7%). The right shoulder was operated in 16 patients (66.7%) and the dominant side in 15 patients (62.5%).

### Implant design and surgical technique

The Aequalis Ascend™ Flex Shoulder System consists of a convertible humeral stem that can be used in an anatomical or reversed configuration. The stem is made of titanium; the voluminous metaphysis is coated with porous titanium. The stabilisation of the stem is achieved by bone ingrowth within the compacted metaphyseal cancellous bone without diaphyseal contact of the tip of the stem.

The surgical technique of the anatomical total shoulder replacement has been described previously [25]. In reverse total shoulder replacement only minimal proximal humeral bone resection was performed and the resected bone was used for glenoid offset augmentation, as described by Boileau et al. [3]. The glenoid implant is anchored to the bone with four screws.

### Clinical evaluation

All patients underwent the same examinations before surgery and at follow-up. Demographic characteristics, diagnosis and postoperative complications were taken from the patients' medical records. Pre- and postoperative Constant score (CS), age- and gender-adjusted Constant score (CS%), subjective shoulder value (SSV) and pain scale score (0: worst to 15: best) were assessed. The disability of arm, shoulder and hand (DASH) score was obtained at follow-up. Shoulder range of motion in abduction (Abd), flexion (Fle) and external rotation (Ext Rot) was measured pre- and post-operatively in all patients. Abduction was measured analogously to the CS as complete abduction with scapulothoracic movement. Abduction strength was quantified using the ISOBEX dynamometer (MDS Medical

Device Solutions AG, Oberburg, Switzerland) according to the recommendation of Constant et al. [6].

### Radiological evaluation

In all patients, standardised digital X-ray images were obtained in three planes (true anteroposterior (AP), axillary, and scapular Y views) before surgery, 6 weeks postoperatively and at regular yearly follow-up. All pre- and postoperative radiographs were analysed for signs of subsidence or evidence of loosening.

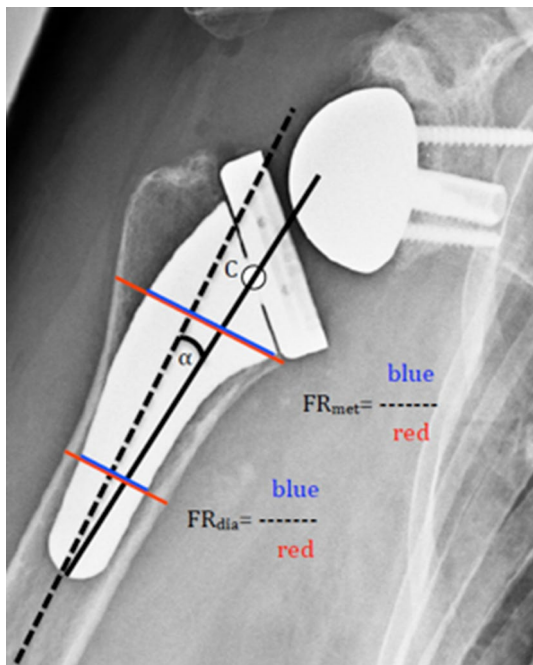
For detailed radiographic analysis patients with posttraumatic conditions and rheumatoid arthritis were not considered. One patient had to be excluded due to a periprosthetic fracture during follow-up. Accordingly, detailed radiographic analysis was performed in 38 shoulders (19 TSR, 19 rTSR). To ensure standardised and comparable images, the AP X-rays were obtained in neutral rotation of the forearm and only small differences in rotation were accepted.

Detailed radiographic analysis included measurement of the inclination of the stem (angle  $\alpha$ ) and the filling ratios of the metaphysis (FR<sub>met</sub>) and the diaphysis (FR<sub>dia</sub>). The measurement procedure for the anatomical prosthesis has already been described [24]. The procedure for the reverse prosthesis was slightly adapted to cater for the different stem design (Fig. 1).

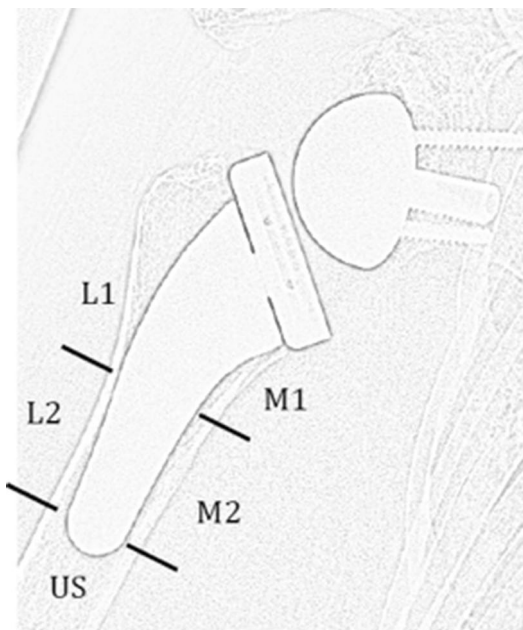
In addition, the quality of the humeral bone remodelling in five different zones around the stem was assessed. The zone system was adopted from Nagels et al. and modified by our study group (Fig. 2) [19, 24]. The characterisation of the humeral bone remodelling was evaluated by two blinded observers (M.S. and S.C.) who were not involved with the design of the prosthesis. In the event of disagreement, the radiograph was discussed and a consensus was reached. The interobserver agreement was calculated.

The zones around the humeral stem were analysed for the three features of bone remodelling: (1) condensation lines (CL) around the tip of the stem; (2) cortical thinning and osteopenia (CNO); (3) spot welds (SW) around the complete humeral component [17, 19]. According to the extent and behaviour of the changes, humeral bone remodelling was rated as low adaptation (0–3 changes in all zones around the stem) or high adaptation (4–6 changes in all zones around the stem, or changes with aggressive behaviour). In the TSR group secondary radiolucent lines around the glenoid were recorded according to Mole [18], and in the rTSR group X-rays were examined to assess glenoid notching according to Sirveaux [27].

Images were analysed using the picture archiving and communication system Image Viewer (Kodak, New York, NY, USA) and a digital light-emitting diode screen with adjustable brightness and contrast.



**Fig. 1** The alpha angle ( $\alpha$ ) was measured between the shaft axis (black dotted line) and a line between the centre (C) of the proximal part of humeral component (solid black line).  $FR_{met}$  is a line perpendicular to the shaft axis, intersecting at the distal-medial border of the humeral platform.  $FR_{dia}$  is a line perpendicular to the shaft axis, intersecting at the distal third of the prosthesis. The filling ratio was defined by the quotient of the blue and red lines at the metaphysis ( $FR_{met}$ ) and at the diaphysis ( $FR_{dia}$ )



**Fig. 2** The five zones that were analysed for humeral bone remodelling: M1 medial 1, M2 medial 2, L1 lateral 1, L2 lateral 2, US under stem

## Statistics

Statistical analysis was performed with SPSS 22.0 software (IBM Corp., Ehningen, Germany). The level of significance was set at  $p < 0.05$ . Differences of preoperative and postoperative continuous data were analysed using the Wilcoxon signed rank test. The Mann–Whitney  $U$  test was used to compare the two groups of patients. Since the study was purely exploratory in design, and multiple tests without adjustment for multiplicity were performed, the reported  $p$  values can be interpreted only descriptively. Interobserver agreement was calculated with Cohen's  $\kappa$ , and agreement strength was inferred in accordance with the recommendations of Landis and Koch [15].

## Results

At final follow-up, all clinical scores (CS, CS% and SSV), the pain scale and the range of motion had improved significantly in both groups ( $p < 0.05$  for all items, Table 1). The DASH score was 15.5 (SD 15.8) in patients with TSR and 35.8 (SD 22.0) in patients with rTSR at follow-up.

In the TSR group, one patient suffered a periprosthetic fracture after a fall on the affected side 23 months after operation and was treated with internal fixation by means of a plate. Two fatigue fractures of the acromion were observed in the rTSR group (8.3%). No patient suffered a deep infection, and there were no other postoperative complications or revisions. None of the TSR had required conversion to rTSR at most recent follow-up.

## Radiographic results

Overall, none of the 53 stems showed evidence of subsidence or loosening. All humeral components were considered well aligned (TSR:  $4.3^\circ$  varus, SD 2.4; rTSR:  $1.7^\circ$  varus, SD 2.6).

For the detailed radiographic assessment of the humeral bone remodelling in the five zones in 38 patients substantial interobserver agreement was found between both examiners ( $\kappa = 0.71$ ). In TSR the most frequent findings were CNO at the calcar ( $n = 7$ , 36.8%) and SW at L2 ( $n = 11$ , 57.9%). None of the patients with TSR had radiolucent lines around the glenoid. In rTSR, CNO was noted in eight patients (42.1%) at M1 and in eight patients at L1 (Table 2, patient example shown in Fig. 3). None of the patients with rTSR had radiographic signs of scapular notching.

Patients with low bony adaptation after TSR ( $n = 14$ , 73.7%) and rTSR ( $n = 17$ , 89.5%) had significantly

**Table 1** Clinical scores and range of motion preoperatively and at most recent follow-up

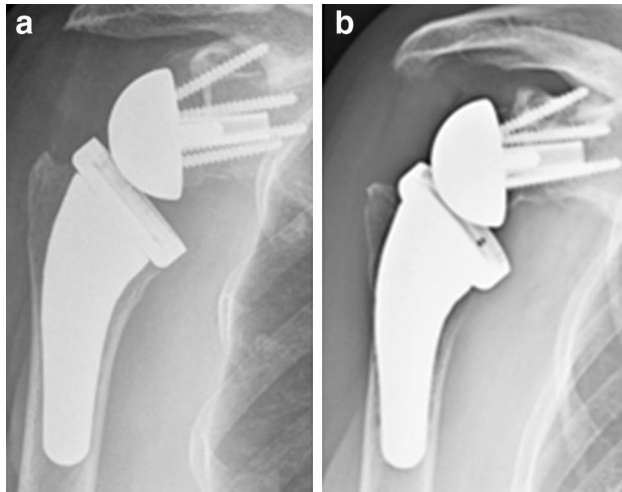
	TSR ( <i>n</i> =29)			Reverse TSR ( <i>n</i> =24)		
	Before operation	At follow-up	<i>p</i> value	Before operation	At follow-up	<i>p</i> value
CS (pts.)	25.0 (SD 11.6)	70.1 (SD 13.7)	<0.001	21.7 (SD 12.9)	57.1 (SD 18.4)	<0.001
CS (%)	33.5 (SD 15.8)	93.7 (SD 18.4)	<0.001	28.8 (SD 17.2)	76.1 (SD 24.5)	<0.001
SSV (%)	39.0 (SD 17.7)	83.7 (SD 16.4)	<0.001	35.1 (SD 21.4)	66.4 (SD 23.4)	0.003
Pain (pts.)	4.5 (SD 3.1)	13.3 (SD 2.2)	<0.001	5.6 (SD 4.2)	13.7 (SD 2.6)	<0.001
Abd (°)	80 (SD 43)	141 (SD 34)	<0.001	59 (SD 27)	125 (SD 41)	<0.001
Fle (°)	90 (SD 39)	139 (SD 37)	<0.001	62 (SD 26)	119 (SD 43)	<0.001
Ext Rot (°)	9 (SD 20)	46 (SD 20)	<0.001	12 (SD 31)	23 (SD 19)	0.039

SD standard deviation

**Table 2** Features of humeral bone remodelling in the five zones

Zone	TSR ( <i>n</i> =19)			rTSR ( <i>n</i> =19)		
	CL	SW	CNO	CL	SW	CNO
M1	0	1 (5.3)	7 (36.8)	0	0	8 (42.1)
M2	2 (10.5)	9 (47.4)	0	0	5 (26.3)	2 (10.5)
L1	1 (5.3)	0	3 (15.8)	0	0	8 (42.1)
L2	2 (10.5)	11 (57.9)	0	0	3 (15.8)	2 (10.5)
US	3 (15.8)	1 (5.3)	0	1 (5.3)	1 (5.3)	1 (5.3)

Results expressed as absolute numbers and percentages

**Fig. 3** A patient with high adaptation after rTSR: cortical bone narrowing and osteopenia in zones M1 and L1 and spot welds in M2 and L2 : (a) at immediate postoperative radiograph and (b) at 23-month follow-up

lower  $FR_{dia}$  than patients with high adaptations (Table 3;  $p=0.005$  and  $p=0.023$ , respectively).

## Discussion

The purpose of our study was to evaluate the clinical and radiological outcome after shoulder replacement using

**Table 3** Filling ratios of patients with low and high bone adaptation

	Low adaptation	High adaptation	<i>p</i> value
TSR	14 (73.7%)	5 (26.3%)	
$FR_{met}$	0.58 (SD 0.08)	0.64 (SD 0.06)	0.156
$FR_{dia}$	0.55 (SD 0.06)	0.66 (SD 0.05)	<b>0.005</b>
rTSR	17 (89.5%)	2 (10.5%)	
$FR_{met}$	0.68 (SD 0.07)	0.75 (SD 0)	<b>0.047</b>
$FR_{dia}$	0.59 (SD 0.05)	0.69 (SD 0.04)	<b>0.023</b>

a cementless short-stem prosthesis system (Ascend™ Flex Shoulder System). The functional scores (CS, CS% and SSV), the pain scale score and the range of motion improved significantly after both TSR and rTSR. At mean follow-up of 25 months (range 20–35), CS% improved from 33.5 (SD 15.8) to 93.7 (SD 18.4) in TSR and from 28.8 (SD 17.2) to 76.1 (SD 24.5) in rTSR (both  $p<0.001$ ). The clinical results in TSR are superior to rTSR, in line with previous reports in the literature [20]. None of the prostheses had to be revised. The complication rate was low after TSR (3.4%) and after rTSR (8.3%).

The clinical results are comparable to those described for other stemless and short-stem shoulder systems [9, 13, 28]. Jost et al. reported on 49 shoulders treated with anatomic comprehensive mini humeral components (Biomet, Warsaw, IN) that were followed up for at least 24 months [13]. The mean CS was 91. Giuseffi et al. described the results of 44 rTSR operations performed using the same



comprehensive mini stem [9]. No functional outcome score was given, but 97% of the patients reported no pain or only mild pain at 2-year follow-up. Recently, Casagrande et al. published the results in 69 patients treated with anatomic TSR using first-generation Ascend™ Flex short-stem prostheses [5]. After minimum follow-up of 24 months, the CS had improved from 39 to 68, comparable to the results of the present study.

Radiographic analysis in a previous study by our group revealed that radiologically detectable bony adaptations frequently occur after insertion of an uncemented short-stem prosthesis [24]. Humeral bone remodelling was not associated with worse clinical outcome, but it may be associated with aseptic loosening in the longer term [21].

In the present study, radiographic analysis showed that 14/19 patients (73.7%) with TSR and 17/19 patients with rTSR (89.5%) had only low bony adaptation at follow-up. In rTSR, higher rates of CNO were found in L1 (41.1 vs. 15.8%), in agreement with previous studies on humeral bone remodelling in reverse shoulder arthroplasty [12, 17].

Interestingly,  $FR_{dia}$  seemed to influence the behaviour of bone adaptations. Patients with high bony adaptation after TSR and rTSR had significantly higher  $FR_{dia}$  than patients with low adaptation ( $p=0.005$  and  $p=0.023$ , respectively). This observation is in agreement with a previous analysis of the Ascend Monolythic™ prosthesis, where higher filling ratios in the metaphysis and the diaphysis were also significantly associated with high bony adaptation [24].

The rate of occurrence of high bony adaptation in anatomical TSR in this study is much lower than in our previous study (26.3 vs. 51.9%). Furthermore, only one patient (Fig. 3) with aggressive behaviour of humeral bone remodelling was seen in the present study, compared to six patients in the earlier study (3.4 vs. 13.6%).

There are two possible factors that may explain the lower rate of humeral bone remodelling in the present study. First, the circumferential porous coating added at the metaphyseal level of the stem may improve bone ingrowth. Alternative bearing surfaces have demonstrated superior wear behaviour in other joint replacements and may prove beneficial in the shoulder as well [8]. Second, the filling ratio may play a major role in humeral bone remodelling. Learning from the observations of the previous study,  $FR_{dia}$  decreased from 0.63 (SD 0.05) to 0.59 (SD 0.06). In both studies, a higher  $FR_{dia}$  was significantly associated with a high rate of humeral bone remodelling. These observations support the theory that a higher filling ratio with close to press-fit fixation in the diaphysis may decrease mineral bone density in the metaphyseal segment because of the lower stress load in this region [17, 19, 24].

This theory is further confirmed by the work of Norris and co-workers [5]. They found radiolucent zones in 71.0% of shoulders treated with the Ascend™ Monolythic, with

8.7% of these joints identified as having humeral stems at risk of future loosening. Six of 73 shoulders (8.2%) had required revision at a mean follow-up of 27.9 months. This considerably high rate of aseptic loosening in the short term may be related to the fact that these prostheses were implanted in press-fit technique, thus with a higher filling ratio, which leads to higher rates of humeral bone remodelling.

In patients with poor bone quality, there might be some limitation for the use of a short-stem shoulder prosthesis. Consequently, if a press-fit fixation of the humeral short-stem is necessary to achieve a stable situation, a longer stem or a cemented short-stem might be favourable to avoid loosening of the humeral stem in longer term.

This study has several limitations. There was no randomisation, and no control group treated with a conventional prosthesis. With a minimum follow-up of only 25 months, no information is provided about the long-term outcome. In addition, only univariate analysis of the relationship between radiographic findings and clinical outcome was carried out. Patient related factors such as gender and age were not analysed. Furthermore, the bone quality was not measured pre- or post-operatively.

## Conclusion

This uncemented short-stem shoulder prosthesis provides good clinical results after both TSR and rTSR at short-term follow-up while a close to press-fit fixation of the short-stem should be avoided to minimize the occurrence of humeral bone remodelling.

## Compliance with ethical standards

**Conflict of interest** Markus Loew received royalties from Fa. Wright, which is related to the subject of this work. No company had any input into the study design, protocol, testing, data analysis, or manuscript preparation. The other authors, their immediate families, and any research foundations with which they are affiliated have not received any financial payments or other benefits from any commercial entity related to the subject of this article.

## References

1. Athwal GS, Sperling JW, Rispoli DM, Cofield RH (2009) Periprosthetic humeral fractures during shoulder arthroplasty. *J Bone Joint Surg Am* 91(3):594–603. doi:10.2106/jbjs.h.00439
2. Bohsali KI, Wirth MA, Rockwood CA Jr (2006) Complications of total shoulder arthroplasty. *J Bone Joint Surg Am* 88(10):2279–2292. doi:10.2106/jbjs.f.00125
3. Boileau P, Moineau G, Roussanne Y, O'Shea K (2011) Bony increased-offset reversed shoulder arthroplasty: minimizing scapular impingement while maximizing glenoid

- fixation. *Clin Orthop Relat Res* 469(9):2558–2567. doi:[10.1007/s11999-011-1775-4](https://doi.org/10.1007/s11999-011-1775-4)
4. Brunner UHF, M.; Rückl, K.; Magosch, P.; Tauber, M.; Resch, H.; Habermeyer, P. (2012) Die schaftfreie Eclipse-Prothese—Indikation und mittelfristige Ergebnisse. *Obere Extremität* 7:22–28. doi:[10.1007/s11678-011-0152-y](https://doi.org/10.1007/s11678-011-0152-y)
  5. Casagrande DJ, Parks DL, Torngren T, Schruppf MA, Harmsen SM, Norris TR, Kelly JD 2nd (2016) Radiographic evaluation of short-stem press-fit total shoulder arthroplasty: short-term follow-up. *J Shoulder Elbow Surg*. doi:[10.1016/j.jse.2015.11.067](https://doi.org/10.1016/j.jse.2015.11.067)
  6. Constant CR, Gerber C, Emery RJ, Sojbjerg JO, Gohlke F, Boileau P (2008) A review of the Constant score: modifications and guidelines for its use. *J Shoulder Elbow Surg* 17(2):355–361. doi:[10.1016/j.jse.2007.06.022](https://doi.org/10.1016/j.jse.2007.06.022)
  7. Deshmukh AV, Koris M, Zurakowski D, Thornhill TS (2005) Total shoulder arthroplasty: long-term survivorship, functional outcome, and quality of life. *J Shoulder Elbow Surg* 14(5):471–479. doi:[10.1016/j.jse.2005.02.009](https://doi.org/10.1016/j.jse.2005.02.009)
  8. Engh CA, Bobyn JD (1988) The influence of stem size and extent of porous coating on femoral bone resorption after primary cementless hip arthroplasty. *Clin Orthop Relat Res* 231:7–28
  9. Giuseffi SA, Streubel P, Sperling J, Sanchez-Sotelo J (2014) Short-stem uncemented primary reverse shoulder arthroplasty: clinical and radiological outcomes. *Bone Joint J* 96-b(4):526–529. doi:[10.1302/0301-620x.96b3.32702](https://doi.org/10.1302/0301-620x.96b3.32702)
  10. Habermeyer P, Lichtenberg S, Tauber M, Magosch P (2015) Midterm results of stemless shoulder arthroplasty: a prospective study. *J Shoulder Elbow Surg*. doi:[10.1016/j.jse.2015.02.023](https://doi.org/10.1016/j.jse.2015.02.023)
  11. Harmer L, Throckmorton T, Sperling JW (2016) Total shoulder arthroplasty: are the humeral components getting shorter? *Curr Rev Musculoskelet Med*. doi:[10.1007/s12178-016-9313-3](https://doi.org/10.1007/s12178-016-9313-3)
  12. Irlenbusch U, Rott O, Braunke M (2015) Inversion of bearing materials in reversed shoulder prostheses. *Obere Extremität* 10 3:173–179. doi:[10.1007/s11678-014-0304-y](https://doi.org/10.1007/s11678-014-0304-y)
  13. Jost PW, Dines JS, Griffith MH, Angel M, Altchek DW, Dines DM (2011) Total shoulder arthroplasty utilizing mini-stem humeral components: technique and short-term results. *Hss J* 7(3):213–217. doi:[10.1007/s11420-011-9221-4](https://doi.org/10.1007/s11420-011-9221-4)
  14. Khan A, Bunker TD, Kitson JB (2009) Clinical and radiological follow-up of the Aequalis third-generation cemented total shoulder replacement: a minimum ten-year study. *J Bone Joint Surg Br* 91(12):1594–1600. doi:[10.1302/0301-620x.91b12.22139](https://doi.org/10.1302/0301-620x.91b12.22139)
  15. Landis JR, Koch GG (1977) An application of hierarchical kappa-type statistics in the assessment of majority agreement among multiple observers. *Biometrics* 33(2):363–374
  16. Lee M, Chebli C, Mounce D, Bertelsen A, Richardson M, Matzen F 3rd (2008) Intramedullary reaming for press-fit fixation of a humeral component removes cortical bone asymmetrically. *J Shoulder Elbow Surg* 17(1):150–155. doi:[10.1016/j.jse.2007.03.032](https://doi.org/10.1016/j.jse.2007.03.032)
  17. Melis B, DeFranco M, Ladermann A, Mole D, Favard L, Nerot C, Maynou C, Walch G (2011) An evaluation of the radiological changes around the Grammont reverse geometry shoulder arthroplasty after eight to 12 years. *J Bone Joint Surg Br* 93(9):1240–1246. doi:[10.1302/0301-620x.93b9.25926](https://doi.org/10.1302/0301-620x.93b9.25926)
  18. Mole DR O, Riand N, Levigne C, Walch G (1999) Cemented glenoid components: results in osteoarthritis and rheumatoid arthritis. *Shoulder Arthroplasty*. Springer, Berlin Heidelberg
  19. Nagels J, Stokdijk M, Rozing PM (2003) Stress shielding and bone resorption in shoulder arthroplasty. *J Shoulder Elbow Surg* 12(1):35–39. doi:[10.1067/mse.2003.22](https://doi.org/10.1067/mse.2003.22)
  20. Nyffeler WR (2014) Design and biomechanics of reverse shoulder prostheses. *Obere Extremität* 9 1:51–56. doi:[10.1007/s11678-013-0241-1](https://doi.org/10.1007/s11678-013-0241-1)
  21. Raiss P, Edwards TB, Deutsch A, Shah A, Bruckner T, Loew M, Boileau P, Walch G (2014) Radiographic changes around humeral components in shoulder arthroplasty. *J Bone Joint Surg Am* 96(7):e54. doi:[10.2106/jbjs.m.00378](https://doi.org/10.2106/jbjs.m.00378)
  22. Sahota S, Sperling JW, Cofield RH (2014) Humeral windows and longitudinal splits for component removal in revision shoulder arthroplasty. *J Shoulder Elbow Surg* 23(10):1485–1491. doi:[10.1016/j.jse.2014.02.004](https://doi.org/10.1016/j.jse.2014.02.004)
  23. Sanchez-Sotelo J, Wright TW, O’Driscoll SW, Cofield RH, Rowland CM (2001) Radiographic assessment of uncemented humeral components in total shoulder arthroplasty. *J Arthroplasty* 16(2):180–187. doi:[10.1054/arth.2001.20905](https://doi.org/10.1054/arth.2001.20905)
  24. Schnetzke M, Coda S, Raiss P, Walch G, Loew M (2015) Radiologic bone adaptations on a cementless short-stem shoulder prosthesis. *J Shoulder Elbow Surg*. doi:[10.1016/j.jse.2015.08.044](https://doi.org/10.1016/j.jse.2015.08.044)
  25. Schnetzke M, Coda S, Walch G, Loew M (2015) Clinical and radiological results of a cementless short stem shoulder prosthesis at minimum follow-up of two years. *Int Orthop*. doi:[10.1007/s00264-015-2770-2](https://doi.org/10.1007/s00264-015-2770-2)
  26. Singh JA, Sperling J, Schleck C, Harmsen W, Cofield R (2012) Periprosthetic fractures associated with primary total shoulder arthroplasty and primary humeral head replacement: a thirty-three-year study. *J Bone Joint Surg Am* 94(19):1777–1785. doi:[10.2106/jbjs.j.01945](https://doi.org/10.2106/jbjs.j.01945)
  27. Sirveaux F, Favard L, Oudet D, Huquet D, Walch G, Mole D (2004) Grammont inverted total shoulder arthroplasty in the treatment of glenohumeral osteoarthritis with massive rupture of the cuff. Results of a multicentre study of 80 shoulders. *J Bone Joint Surg Br* 86(3):388–395
  28. von Engelhardt LV, Manzke M, Filler TJ, Jerosch J (2015) Short-term results of the reverse total evolutive shoulder system (TESS) in cuff tear arthropathy and revision arthroplasty cases. *Arch Orthop Trauma Surg* 135(7):897–904. doi:[10.1007/s00402-015-2218-6](https://doi.org/10.1007/s00402-015-2218-6)
  29. Werner BC, Dines JS, Dines DM (2016) Platform systems in shoulder arthroplasty. *Curr Rev Musculoskelet Med*. doi:[10.1007/s12178-016-9317-z](https://doi.org/10.1007/s12178-016-9317-z)
  30. Wutzler S, Laurer HL, Huhnstock S, Geiger EV, Buehren V, Marzi I (2009) Periprosthetic humeral fractures after shoulder arthroplasty: operative management and functional outcome. *Arch Orthop Trauma Surg* 129(2):237–243. doi:[10.1007/s00402-008-0746-z](https://doi.org/10.1007/s00402-008-0746-z)