

## Neer Award 2005: The Grammont reverse shoulder prosthesis: Results in cuff tear arthritis, fracture sequelae, and revision arthroplasty

Pascal Boileau, MD, Duncan Watkinson, FRCS, Armodios M. Hatzidakis, MD, and Istvan Hovorka, MD, Nice, France

*This clinical study was performed to analyze the mid-term results and potential complications of the reverse prosthesis in different diagnosis. Forty-five consecutive patients with Grammont prosthesis were evaluated clinically and radiographically with a mean follow-up of 40 months (range, 24-72 months). The indication was a massive and irreparable cuff tear associated with arthrosis (CTA) in 21 cases, fracture sequelae (FS) with arthritis in 5 cases, and failure of a revision arthroplasty (revision) in 19 cases. Fourteen complications occurred in 11 patients. 3 dislocations, 3 deep infections (all 3 in the revision group), 1 case of aseptic humeral loosening, 2 periprosthetic humeral fractures, 1 intraoperative glenoid fracture, 1 wound hematoma, 2 late acromial fractures, and 1 axillary nerve palsy. Of the patients, 10 (22%) required further surgery: 4 reoperations, 4 prosthesis revisions, and 2 prosthesis removals. Complications were higher in revision than in CTA (47% vs. 5%). All 3 groups showed a significant increase in active elevation (from 55° preoperatively to 121° postoperatively) and Constant score (from 17 to 58 points) but no significant change in*

*active external rotation (from 7° to 11°) or internal rotation (S1 preoperatively and postoperatively). Of the patients, 78% were satisfied or very satisfied with the result and 67% had no or slight pain. However, the postoperative Constant score, adjusted Constant score, and American Shoulder and Elbow Surgeons shoulder score were all significantly higher in the CTA group with as compared with the revision group ( $P = .01$ ,  $.004$ , and  $.002$ , respectively). Scapular notching was seen in 24 cases (68%). No glenoid loosening was observed at current follow-up, even when the notch extended beyond the inferior screw (28% of cases). Atrophy of severe fatty infiltration of the teres minor was associated with lower external rotation (15° vs 0°,  $P = .02$ ) and lower functional results (Constant score of 46 points vs 66 points,  $P < .007$ ). The Grammont reverse prosthesis can improve function and restore active elevation in patients with incongruent cuff-deficient shoulders; active rotation is usually unchanged. Results are less predictable and complication and revision rates are higher in patients undergoing revision surgery as compared with those in patients with CTA. Results of the reverse prosthesis depend on the diagnosis and on the remaining cuff muscles, specifically the teres minor. Surgeons should be vigilant with regard to low-grade infection in revision surgery. (*J Shoulder Elbow Surg* 2006;15: 527-540.)*

From the Department of Orthopaedic Surgery and Sports Traumatology, Hôpital de L'Archet, University of Nice.

This study received the Charles Neer Award at the annual American Shoulder and Elbow Surgeons meeting, Washington, DC, February 2005.

No benefits in any form have been or will be received from a commercial party related directly or indirectly to the subject of this article. No funds were received in support of this study.

Reprint requests: Pascal Boileau, MD, Professor and Chairman, Department of Orthopaedic Surgery and Sports Traumatology, Hôpital de L'Archet, University of Nice, 151, Route de St Antoine de Ginestière, 06202 Nice, France (E-mail: boileau.p@chu-nice.fr).

Copyright © 2006 by Journal of Shoulder and Elbow Surgery Board of Trustees.

1058-2746/2006/\$32.00

doi:10.1016/j.jse.2006.01.003

**S**houlder arthroplasty via an unconstrained prosthesis is a well-tested procedure and, in most cases, provides excellent pain relief and improved function.<sup>9,34,46</sup> However, in situations in which a damaged and incongruent glenohumeral joint is associated with a deficient or nonfunctional rotator cuff, the results are often much less satisfactory.<sup>17</sup> In practice,

there are at least 3 situations in which surgeons must face this challenging combination: first, in cases of arthritis associated with a massive and irreparable cuff tear; second, in cases of fracture sequelae in which distortion of the proximal humeral anatomy around the cuff insertion results in a functionally useless cuff; and third, in cases of revision after failure of a previous arthroplasty in which the cuff is deficient, scarred, or retracted or has undergone fatty infiltration.<sup>2,5,50</sup>

In such incongruent and rotator cuff-deficient shoulders, the forces that normally counteract the upward component of the deltoid and stabilize the center of rotation of the shoulder are lost; as a result, deltoid contraction tends to cause the ascension of the humerus, rather than the rotatory movement necessary for elevation of the limb.<sup>2,17,19,21,38</sup> When a shoulder arthroplasty is performed in this difficult biomechanical environment, the standard of care is an unconstrained hemiarthroplasty, accepting Neer's "limited goals" (pain relief but restricted function).<sup>1,20,32,34,37,42,49,52</sup> Many constrained prostheses have been introduced to exceed these limited goals, without success. Some provided good pain relief, but active elevation was usually under 90°. <sup>4,11,30,39,45,51</sup> Furthermore, none of these designs have been able to withstand the increased stresses that their fixed fulcrum imposed on the bone-prosthesis interface, leading to early failure and abandonment of these designs.<sup>8,29,31,33,39</sup>

The Grammont reverse prosthesis was developed to provide a solution to this dilemma, restoring mobility around a stable center of rotation and avoiding early loosening.<sup>23,24</sup> The Grammont prosthesis is not fully constrained, but it does have congruent joint surfaces, making it a semiconstrained prosthesis. Unlike previous reverse ball-and-socket designs, the Grammont uses a large hemispherical glenoid component with no neck. This means that the center of rotation of the shoulder joint (the center of the sphere) is actually situated at the glenoid bone-prosthesis interface, minimizing torque on the component.<sup>6,24</sup> In addition, the Grammont has a congruent polyethylene humeral cup, implanted with a nonanatomic, more horizontal inclination of 155°. This has the advantage of lowering the humerus, thereby placing the deltoid muscle under tension to provide a stable and biomechanically stronger fulcrum.<sup>6</sup> This stable fulcrum is essential for active elevation in a shoulder with a severely deficient unbalanced rotator cuff.

This clinical study was performed to analyze the midterm results and potential complications of the Delta prosthesis in 3 groups of patients: those with massive and irreparable cuff tear arthrosis (CTA), those with fracture sequelae (FS), and those who needed revision surgery after failure of a previous arthroplasty.

## MATERIALS AND METHODS

The Delta shoulder prosthesis (Depuy-International Ltd) is a reverse ball-and-socket prosthesis that was designed in 1985 by Professor Paul Grammont in Dijon, France.<sup>23,24</sup> The glenoid component was, initially, a cemented barrel (two thirds of a sphere) that fit around the glenoid. This design was changed to the current hemispherical configuration in 1991 because of initial problems with loosening.<sup>6</sup> The original hemispheric component was fixed to the glenoid baseplate via a peripheral thread. This design was changed after unscrewing of the glenosphere from the metaglène occurred, mainly in right shoulders, as active forward flexion produced a ratchet-like effect. This problem was solved in 1996 when the peripheral thread was changed to a Morse taper with a central, countersunk screw. Our experience began in 1997, after these initial problems were addressed, and the design has since remained unchanged.

The glenoid component consists of 2 parts: a baseplate (the metaglène), 29 mm in diameter, to which a polished hemisphere (the glenosphere) is secured. The metaglène, which has a roughened hydroxyapatite-coated surface, is fixed to the glenoid via a central peg and 4 divergent screws. The superior and inferior screws are aimed at the coracoid base and the inferior pillar of the scapula, respectively, for optimal hold. Their heads are threaded to lock into the metaglène at an angle of 120° relative to each other. The anterior and posterior screws are nonlocking and are inserted at a free angle. The glenosphere is available in a diameter of either 36 mm or 42 mm.

The humeral component consists of a circular stem with a modular neck component and a polyethylene cup. The inclination of the neck of the humeral prosthesis is 155°. The stem and neck are available with either a polished surface for cementing or a hydroxyapatite-coated surface for press-fit application. The stem is available in 3 lengths (100, 150, or 180 mm) and 4 diameters (6, 9, 12, or 15 mm). The neck diameter is either 36 mm or 42 mm, corresponding to the humeral cup. The polyethylene cup is 6 mm thick and is also available in a more constrained configuration for instability problems; other thicknesses are now available (3, 6, and 9 mm). Finally, a neck extension may be added between the neck and the cup to further increase the offset and tension.

The No. 3 in the name of the prosthesis refers to the reverse design. The Delta 1 prosthesis is a hemiarthroplasty with a metal humeral head inserted onto the humeral neck component instead of the humeral cup. The Delta 2 prosthesis is a standard-configuration total shoulder prosthesis with the ball on the humerus and a polyethylene cup inserted onto the metaglène. Because they share the same stem, a Delta 3 prosthesis can be converted to a Delta 1 hemiarthroplasty should a major problem occur with the glenoid component, either at the time of operation or subsequently.

### Operative technique

Grammont originally described a transacromial approach but subsequently considered using a deltopectoral approach.<sup>23,24</sup> We used a superior, transdeltoid approach (cuff approach) for our first 4 cases but then changed to a classic deltopectoral approach for 2 reasons.<sup>26</sup> We were

concerned about possible damage to the deltoid muscle, the sole motor for this prosthesis. Furthermore, access to the humeral diaphysis was sometimes necessary, especially in the revision and FS groups.

Even with a massive cuff tear, the inferior third of the subscapularis tendon was often found to be partially intact. This was, therefore, released from the lesser tuberosity, as in a standard shoulder arthroplasty, and preserved for reinsertion at the end of the procedure by use of transosseous, nonabsorbable No. 5 Ethibond sutures (Ethicon, Somerville, NJ).

Revision cases and FS cases were more complex. The superior cuff sometimes appeared to be in continuity, but closer inspection invariably showed that this was nothing more than a thin layer of nonfunctional fibrous tissue. This superior cuff remnant was excised to obtain adequate exposure. In FS cases, the tuberosities were either malunited or nonunited. Indeed, in many cases, all that remained was a thin shell of cortical bone attached to a retracted and scarred cuff. The tuberosities' abnormal position often constituted a physical block to joint movement, necessitating excision. In 3 cases, it was possible either to preserve the tendons or to reattach the tuberosities to the prosthetic neck at the end of the procedure.

A jig was used to make the humeral cut with an inclination of 155° and approximately 20 to 30° of retroversion, by use of the forearm as a reference. Although it has been recommended to implant this prosthesis with 0° to 10° of retroversion, we chose 20° to 30° of retroversion to alter the native anatomy of the proximal humerus as little as possible; more specifically, we strove to avoid destruction of the lesser tuberosity during humeral preparation (for reattachment of the subscapularis on its footprint). If the bone appeared fragile, further humeral preparation was deferred until the glenoid components were in place. Otherwise, sequential reamers were used to open and prepare the humeral canal; next, a special conical reamer was used to shape the metaphysis. The trial prosthesis (minus the trial cup) was left in place to protect the proximal humerus during glenoid preparation. We cemented the stems and used a cement restrictor in all cases. The humeral polyethylene liner was then impacted on the humeral component. A relatively tight trial reduction was sought to ensure adequate tension of the deltoid. In cases of severe bone loss of the proximal humerus (those with FS or after revision arthroplasty), bilateral, scaled radiographs of both humeri were taken. A tracing was made to assess the length of the bone loss of the deficient humerus and to estimate the height at which the prosthesis should be cemented to maintain stability.

Adequate exposure of the glenoid is essential because the Delta reamers and components are more bulky than those used in a standard total shoulder arthroplasty. To achieve the necessary release, an anterior and inferior release of the capsule from the glenoid was performed to allow posterior dislocation of the humerus.

After placement of 2 fork retractors on the glenoid, 1 anterior and 1 posterior, a central hole was drilled for the central peg of the metaglene; this also served as a pilot hole for the reamers. After the remaining subchondral bone was reamed to a flat and uniform surface, holes were drilled at the periphery of the glenoid surface with a 3.2-mm drill to obtain bone bleeding and to aid secondary fixation of the

hydroxyapatite-coated metaglene. The metaglene was then impacted into position. The anterior and posterior screws were placed first, to obtain compression between the metaglene and the glenoid bone. Fixation was augmented with the upper and lower divergent locking screws.

Finally, the glenosphere was fixed to the metaglene, by first impacting the Morse taper and then tightening the central screw. A 36-mm glenosphere was used in all but 4 cases (large men) in which a 42-mm glenosphere was used.

Intraoperative determination of deltoid tension may be difficult, guided mostly by surgical experience. A tight reduction is the only rubric; with the arm at the side and the elbow extended, the conjoined tendon should feel tensioned after reduction.<sup>6</sup> In CTA cases, the prosthesis was usually stable, as a minimal bone cut had been made on the humerus and the glenosphere had been implanted low on the glenoid surface. In revision or FS cases, stability was often more difficult to attain: the humeral prosthesis was cemented proud, and additional cup thickness (3, 6, or 9 mm) was added if needed. We avoided the more constrained cup, as we believed that the additional constraint on the glenoid would increase the shear forces and, therefore, the risk of glenoid loosening. If the prosthesis was felt to be too tight (ie, not possible to reduce), the humerus was recut as needed.

The subscapularis tendon, or at least part of it, was reinserted with transosseous sutures in most cases. A biceps tenodesis was systematically performed by suturing the tendon to the pectoralis major tendon after resection of the intraarticular portion of the biceps.

Postoperatively, the patient's arm was placed in a simple sling. Patients were encouraged to perform self-rehabilitation with pendulum exercises for 5 minutes, 5 times a day. After 3 weeks, rehabilitation was started with a physiotherapist who was instructed to mobilize the arm above the horizontal level in the plane of the scapula. The combination of abduction at 90° with external rotation (throwing position) was not allowed, as it placed the prosthesis at risk for anterior dislocation. In patients who were at high risk for prosthetic instability (revision), immobilization with an abduction splint at 60° was used for 4 weeks.

### *Patients*

Over a 5-year period, starting in 1997, 50 consecutive Grammont shoulder replacements were performed either by the senior author (P.B.) or under his direct supervision. All patients were prospectively followed up clinically and radiographically on a regular basis: at 3, 6, and 12 months and then yearly after the procedure. Of the patients, 5 were excluded: 2 had died, 1 had had a debilitating cerebrovascular accident (unrelated to surgery), and severe dementia (Alzheimer's disease) developed in 1. The last excluded patient underwent reconstruction with a custom reverse prosthesis after tumor excision.<sup>15</sup> Forty-five patients were available for clinical analysis. The mean follow-up was 40 months (range, 24-72 months).

The patients were divided into 3 groups, according to etiology: massive and irreparable CTA, sequelae of a proximal humeral fracture (FS), and revision prosthesis after failure of a previous arthroplasty (revision). Pain, associated with stiffness or pseudoparalysis of the shoulder (ineffective shrug because of anterosuperior subluxation of the

humeral head), was the primary indication for surgery in each of the 3 subgroups.

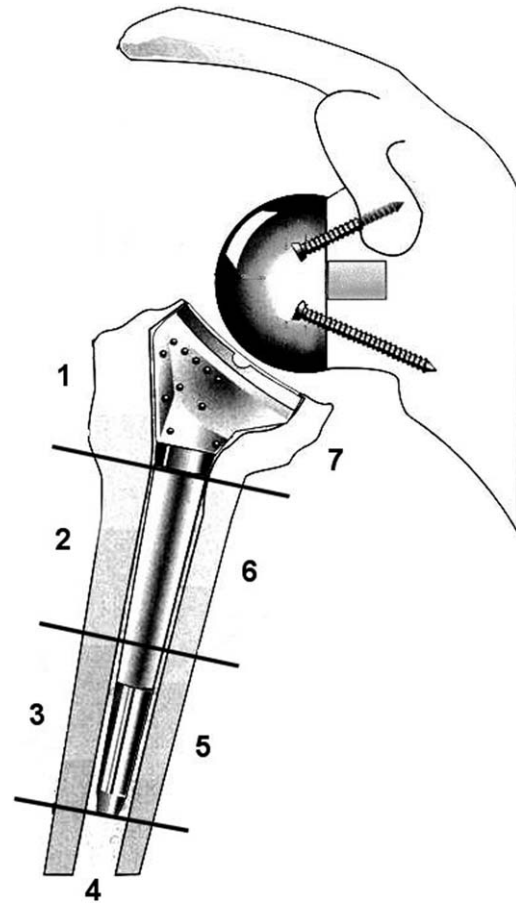
The CTA group consisted of 21 patients with a mean age of 77 years (range, 67-86 years). They were significantly older ( $P = .0002$ ) than those in the revision and FS groups. Of the patients in the CTA group, 19 were women (90%), and the dominant side was involved in 86%. All patients had persistent pain and pseudoparalysis of the shoulder. All had been treated with pain medications, antiinflammatory medications, and physical rehabilitation for at least 6 months. Two had lost active elevation after extensive subacromial decompression surgery: one overaggressive acromioplasty and one anterior acromionectomy complicated by postoperative avulsion of the anterior deltoid. According to the radiologic classification of Hamada et al,<sup>27</sup> there were 3 patients with grade II changes (upward migration of the humeral head but no significant acetabularization), 6 with grade III changes (concavity of the acromial undersurface with acetabularization), 10 with grade IV changes (grade III changes plus narrowing of the glenohumeral joint), and 2 with grade V changes (humeral head collapse).

There were 5 patients in the FS group. The mean age was 72 years (range, 66-79 years), 3 were women (80%), and the dominant side was involved in 2 cases (40%). The failed initial treatment was percutaneous pinning in 2 cases and conservative treatment in 3. The 5 patients had a painful and stiff shoulder. According to the classification of FS described by Boileau et al,<sup>5</sup> there were 3 type 4 sequelae (severe malunion or nonunion of the tuberosities), 1 type 3 (surgical neck nonunion) with osteonecrosis of the humeral head, and 1 type 1 (valgus impacted malunion) with previous tuberculous arthritis and a massive cuff tear.

There were 19 patients in the revision group. The mean age was 67 years (range, 50-87 years), and 14 were women (70%). The dominant side was involved in 53%. Three patients had persistent pain and pseudoparalysis of the shoulder after previous surgery for cuff tear arthritis: failed Bi-Polar hemiarthroplasties (Biomet, Warsaw, IN) in two and failed arthrodesis (excessive abduction and internal rotation) in one. In the other 16 patients, shoulder replacement performed for a displaced proximal humeral fracture had failed. The reason for failure was a tuberosity migration or nonunion in 14 cases and prosthesis malposition with a cuff tear in 2. Revision surgery was performed as a 2-stage procedure in 4 of these patients, because they had a concomitant deep infection.

### Clinical analysis

Patient files were reviewed to determine preoperative range of motion (ROM) and Constant score.<sup>10</sup> The adjusted Constant score was calculated as a percentage of normal reference values matched for age and sex.<sup>10</sup> Preoperative computed tomography (CT) arthrograms and operation notes were examined to determine the condition of the cuff muscles and the glenoid bone stock. ROM and Constant score were recorded at each follow-up visit, and the final examination was performed by 2 independent observers (D.W. and A.M.H.). Patients were then asked to complete the American Shoulder and Elbow Surgeons (ASES) shoulder questionnaire (which includes a visual analog scale for



**Figure 1** Classification of humeral zones: the humerus was divided into 7 zones around the prosthesis.

pain) and to rate their level of satisfaction on a 4-point scale (very satisfied, satisfied, no better and no worse, or worse).

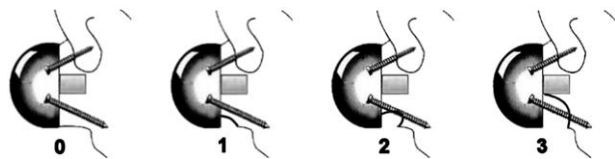
### Radiographic analysis

Fluoroscopically controlled radiographs with a minimum 2-year follow-up were available for 42 patients. Radiologic assessment included an anteroposterior view tangential to the baseplate, a scapular lateral view, and an axillary view. The radiographs were examined for notching at the inferior margin of the scapular neck and for glenoid and humeral radiolucent lines.

Humeral radiolucent lines were classified according to width ( $<2$  mm or  $\geq 2$  mm) and number of zones involved. The humerus was divided into 7 zones around the prosthesis as shown in Figure 1. Zones 1 and 7 were at the level of the neck component, zones 2 and 6 were at the proximal half of the stem component, and zones 3 and 5 were at the distal half of the stem component.<sup>41</sup>

Glenoid radiolucent lines were classified according to their width ( $<2$  mm or  $\geq 2$  mm), and the involvement of individual zones was analyzed. Glenoid zones were defined as follows: 1, superior baseplate; 2, inferior baseplate (independent from a notch if present); 3, central pillar; and 4, screws.<sup>44</sup>





**Figure 2** Classification of extent of notch: 0, no notch; 1, small notch stopping short of inferior screw; 2, medium notch reaching inferior screw; 3, large notch extending beyond inferior screw.

Glenoid notching is a documented feature of the Delta 3 prosthesis and is thought to be due to impingement of the humeral cup against the inferior scapular neck.<sup>6,44,47</sup> The extent of the notch was classified in relation to the inferior screw as shown in Figure 2.

#### Preoperative cuff status

A preoperative CT arthrogram was obtained to evaluate the trophicity and fatty infiltration of the cuff muscles and to assess the potential bone loss of the glenoid. A preoperative CT arthrogram was available in 19 patients in the CTA group, 13 in the revision group (although a metal artifact limited the interpretation in 2 cases), and 3 in the FS group. Fatty infiltration of the subscapularis, infraspinatus, and teres minor was classified by use of a simplified version of the system of Goutallier et al.<sup>22</sup> Grades 0, 1, and 2 were grouped together (<50% fatty infiltration), as were grades 3 and 4 ( $\geq$ 50% fatty infiltration).

The subscapularis was intact in 19 cases, partially torn in 9, and completely torn in 11; fatty infiltration was less than 50% in 16 cases and greater than 50% in 19. The supraspinatus was intact in 3 cases and completely torn in 34; fatty infiltration was less than 50% in 6 cases and greater than 50% in 27. The infraspinatus was intact in 4 cases, partially torn in 9, and completely torn in 24; fatty infiltration was less than 50% in 8 cases and greater than 50% in 26. The teres minor was intact in 35 cases and torn in 2; fatty infiltration was less than 50% in 23 cases and greater than 50% in 12.

#### Statistical analysis

Statistical analysis was performed on preoperative and postoperative data by use of the Student *t* test for continuous data and  $\chi^2$  test for nominal data.

## RESULTS

#### Complications

In total, 14 complications occurred in 11 patients (24%). These are summarized in Table I. Of these, 9 occurred in the revision group, 4 in the CTA group, and 1 in the FS group.

There were 2 acromial fractures that appeared as incidental findings on the 3-month postoperative radiographs. Neither patient could recall any trauma; both were completely asymptomatic, and there did not appear to be any detrimental effect on function (Constant scores of 69 and 77 points and active elevation of 140° and 130°).

There was 1 axillary nerve palsy, representing the only serious complication in the CTA group. After 3 years, recovery remained limited. Both ROM and function were poor, with active elevation limited to 50° and a Constant score of 9 points. The nerve was identified during the procedure and was intact. We are unsure of the etiology of the palsy, but we suspect that the nerve may have been stretched by the lowering of the humerus. The patient declined any further surgery.

Of the patients, 10 (22%) needed further surgery: 4 reoperations without a humeral stem or glenoid revision, 4 prosthetic revisions, and 2 prosthesis removals. These are broken down per group in Table II.

#### Reoperations

A reoperation was defined as surgery without revision of the prosthesis. Exchange of the interface was not considered as a revision of the prosthesis. Four patients underwent reoperation with or without a change of the interface components: one in the CTA group and three in the revision group.

One patient underwent evacuation of a wound hematoma after the procedure. She had no further wound problems.

Three prosthetic dislocations occurred. Two of them occurred around 1 month when the brace was removed. They were both in the revision group and were successfully treated by adding an extension to the humeral neck component to increase the offset and tension. The third dislocation occurred in the CTA group 6 months after the operation. At reoperation, a damaged polyethylene humeral cup was exchanged. The patient underwent immobilization in neutral rotation for 6 weeks and had no further dislocations. These 4 patients were all included for analysis of the results, because the initial prosthesis was still in place at review and they had more than 2 years of follow-up after the reoperation.

#### Prosthesis revision and removal

A revision was defined as surgery with a change of the prosthesis. There were no revisions or prosthesis removals in the CTA group.

One prosthesis was revised in the FS group because of an intraoperative glenoid fracture. The glenoid fracture occurred during reaming of the glenoid. Intraoperatively, the fixation of the baseplate seemed to be sufficient, but the postoperative radiographs showed malpositioning and migration of the glenoid component. The patient underwent revision the next day, and the reverse prosthesis was converted to a hemiarthroplasty (Delta 1). At the last follow-up, the result remained poor, with 40° of active elevation and persistent shoulder pain.

Three deep infections occurred in the months after

**Table I** Complications and treatment

Complications (N = 14)	No.	Treatment
Axillary nerve palsy	1	—
Late acromial fracture	2	—
Hematoma	1	Evacuation
Dislocation	3	Reoperated: cup extension in 2 and change of polyethylene cup in 1
Intraoperative glenoid fracture	1	Revised to hemiarthroplasty (Delta 1 prosthesis)
Deep infection	3	Revised: prosthesis removed in 2 and exchanged in 1
Aseptic humeral loosening	1	Revised to cemented long stem
Periprosthetic humeral fracture	2 (1 perioperative and 1 late traumatic)	Immobilization in 1 and revised to long stem in 1

**Table II** Number of reoperations, prostheses revised, and removals in the 3 groups and overall series

	Reoperation (excluding revision)	Prosthesis revised	Prosthesis removed	Total
CTA (n = 21)	1	—	—	1 (5%)
FS (n = 5)	—	1	—	1 (20%)
Revision (n = 19)	3	3	2	8 (45%)
Overall series (N = 45)	4 (9%)	4 (9%)	2 (4%)	10 (22%)

the reverse prosthesis was implanted. All 3 occurred in the revision group. The first patient had a persistently inflamed wound from the time of operation. In the second, whose index surgery was a staged procedure because of previous infection, recurrent infection developed 12 months postoperatively, after a good initial recovery. These 2 patients with overt infection underwent resection arthroplasty at 16 and 18 months. After this, active elevation was 40° and 50°, respectively, and the Constant score was 13 and 22 points, respectively. In the third patient, septic loosening of the humeral component developed, also around the 12-month mark. This prosthesis was revised in 1 stage to change the reverse prosthesis.

Two other patients, also in the revision group, underwent revision. In 1 patient with a cemented stem, early, aseptic humeral loosening developed and revision was performed 1 year postoperatively. Intraoperative cultures were negative. At 28 months, the prosthesis remained well fixed; active elevation was 100°, and the Constant score was 34 points. Another patient underwent revision for a comminuted periprosthetic humeral fracture after a motorcycle accident. This patient underwent revision to a long-stem reverse prosthesis with cerclage of the bone fragments. The fracture healed, but the results have remained poor, with a Constant score of 36 points and active elevation of 70°.

### Clinical results

From 1997 to 2002, the Grammont prosthesis was implanted in 45 patients. Three patients required revision surgery but retained their prostheses. Follow-up for these patients was longer than 2 years, so their results were included in the following sections. Two patients eventually required resection arthroplasty, and one patient was converted to a Delta 1 prosthesis (see "Complications" section). These cases were counted as clinical failures and have been excluded from further clinical or radiologic analysis, leaving 42 patients with a mean follow-up of 40 months. There was no significant difference in follow-up between the CTA and revision groups. The FS group was too small to allow any meaningful comparison to the other 2 groups.

Preoperative and most recent active ROM and pain data are shown in Table III. There was a significant gain in active anterior elevation in all 3 groups ( $P = .01$  in the FS group and  $P < .001$  in the other 2 groups). There was a small increase in active external rotation in the CTA and FS groups and a small decrease in the revision group, but none of these were significant, given the numbers available.

The proportion of patients with no or slight pain (score on visual analog scale  $< 3/10$ ) was 81% in the CTA group, 36% in the revision group, and 50% in the FS group. The pain score was significantly better in the CTA group when compared with the revision group ( $P = .01$ ).

The Constant score demonstrated a significant increase in all 3 groups (Table IV). However, the increase was significantly greater in the CTA group when compared with the revision group ( $P = .01$ ).

The adjusted ASES shoulder scores and Constant scores were significantly higher in the CTA group as compared with the revision group ( $P = .004$  and  $.002$ , respectively) (Figures 3 and 4).

All but 4 of 45 patients believed that they had benefited from the operation. In the CTA group, 17 were very satisfied, 3 were satisfied, and 1 was worse. The patient who stated that she was worse had an axillary nerve palsy postoperatively that has not

**Table III** Active ROM (preoperatively and at latest follow-up) for the 3 groups and overall series

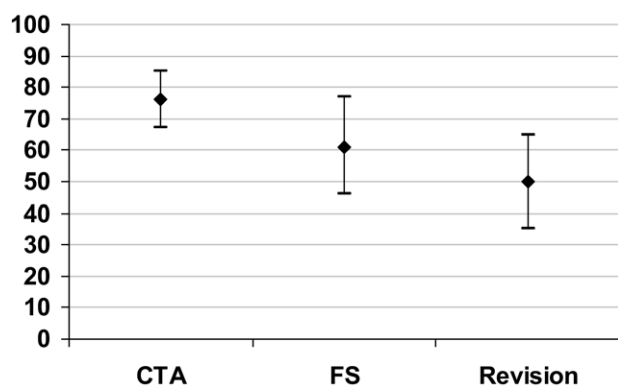
	Anterior elevation (°) [mean (95% CI)]		External rotation (°) [mean (95% CI)]		Internal rotation		Pain score (visual analog scale)
	Preoperative	Follow-up	Preoperative	Follow-up	Preoperative	Follow-up	
CTA (n = 21)	53 (41 to 65)	123 (108 to 139)	9 (1 to 16)	14 (7 to 21)	S1	L3	1.7/10 (0.4 to 2.9)
FS (n = 4)	56 (44 to 68)	122 (96 to 148)	-2 (-12 to 8)	9 (-10 to 28)	GT	D12	2.6/10 (0.4 to 4.8)
Revision (n = 17)	56 (44 to 68)	113 (100 to 126)	8 (-2 to 19)	1 (-6 to 7)	S1	L5	4.5/10 (3.1 to 6.0)
Overall series (N = 42)	55 (47 to 63)	121 (111 to 131)	7 (1 to 13)	11 (5 to 16)	S1	S1	3.2/10 (1.6 to 4.8)

CI, Confidence interval.

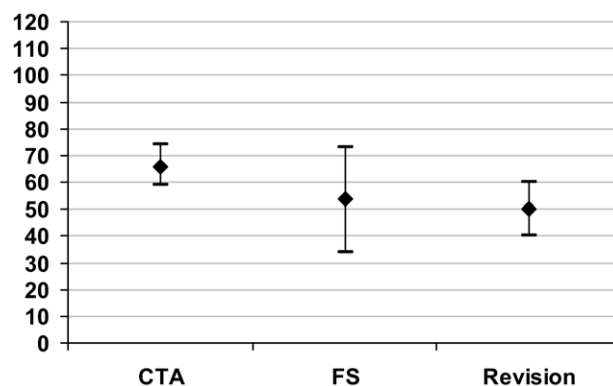
**Table IV** Constant score for the 3 groups and overall series preoperatively and at latest follow-up

	Constant score		Gain	P value
	Preoperative	Follow-up		
CTA (n = 21)	18 (14-22)	66 (58-74)	49 (41-56)	P < .001
FS (n = 4)	15 (9-21)	61 (44-78)	42 (26-59)	P = .008
Revision (n = 17)	15 (11-19)	46 (37-55)	32 (22-42)	P < .001
Overall series (N = 42)	17 (14-19)	58 (51-64)	41 (35-47)	P < .001

CI, Confidence interval.



**Figure 3** Mean ASES shoulder score by group with 95% confidence intervals.



**Figure 4** Mean adjusted Constant score by group with 95% confidence intervals.

recovered. In the revision group, 11 were very satisfied, 3 were satisfied, and 3 were no better and no worse. In the FS group, 3 were very satisfied and 2 were no better and no worse.

Although there was no significant difference in external rotation among the groups, the preoperative status of the teres minor did appear to be an important factor. Mean active external rotation was 15° in patients with less than 50% fatty infiltration, as opposed to 0° in those with more than 50% ( $P = .02$ ). The mean Constant score was also significantly better in the former group (66 points vs 46 points,  $P = .007$ ).

We were unable to demonstrate any significant effect of the preoperative condition of the infraspinatus (tear or fatty infiltration) on postoperative external

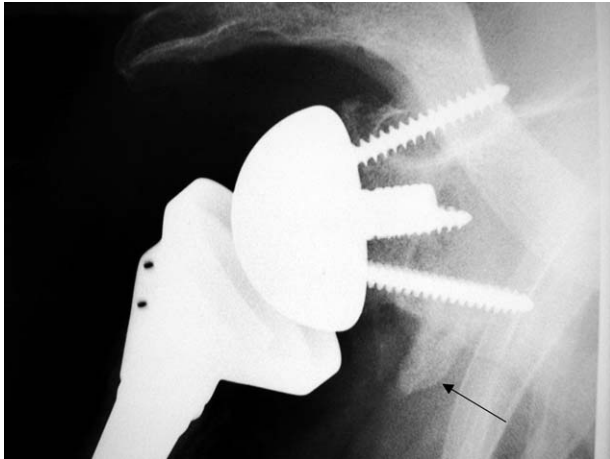
rotation or function. However, only 4 patients had a completely intact tendon, and only 7 had less than 50% fatty infiltration, so this finding should be interpreted with caution.

The belly-press test was positive in 22 patients postoperatively, but neither this nor the preoperative state of the subscapularis had any significant effect on either movement or functional scores.

#### Radiologic results

After exclusion of the 4 cases of failure, radiologic analysis was possible for 38 patients.

**Glenoid components.** With regard to glenoid components, a radiolucent line was seen in zone 1 (superior part of the baseplate) in 17 cases (45%), but only



**Figure 5** Notching (bone lysis) of scapular neck with formation of bony spur (arrow).

one of these exceeded 2 mm and none appeared to be progressive. No radiolucent lines were seen in any other zones.

**Scapular notching.** Scapular notching was seen in 26 cases (68%). Of these, 18 were grade 1, 5 were grade 2, and 5 were grade 3. There was notching extending to or beyond the inferior screw in 26% of cases. However, neither the presence nor the size of the notch had a negative effect on the Constant score, the adjusted Constant score, or the ASES score.

**Humeral components.** With regard to humeral components, radiolucent lines less than 2 mm wide were seen in 23 cases (60%); these involved 1 zone in 10 cases, 2 zones in 8, 3 zones in 3, 4 zones in 1, and 5 zones in 1. Radiolucent lines greater than 2 mm were seen in 6 cases (16%); 5 were progressive. One zone was involved in 2 cases, and two zones were involved in 4.

**Heterotopic ossification.** Heterotopic ossification was seen in 17 cases (45%). It occurred at the lower margin of the glenoid and was usually minor; however, we also noticed a bony spur at the inferior margin of the scapular neck in 24 cases (63%). This always occurred in association with a notch and often tended to make the notch appear deeper than it really was. The spur was always located at the medial border of the notch, adjacent to the point of impingement between the humeral cup and the scapular neck (Figure 5).

## DISCUSSION

Constrained prostheses, both anatomic and reverse ball-and-socket, have a reputation for early failure.\* The Grammont prosthesis is not fully constrained, but it does have congruent joint surfaces,

making it a semiconstrained prosthesis.<sup>23,24</sup> Grammont initially designed the Delta prosthesis for patients with arthritis due to a massive cuff tear (ie, "cuff tear arthritis") (Figure 6).<sup>24</sup> Another potential indication for a reverse prosthesis is FS, where distortion of the proximal humeral anatomy around the cuff insertion results in a functionally useless cuff (Figure 7). Results of conventional, unconstrained arthroplasty in these cases are often unpredictable because a greater tuberosity osteotomy and refixation (needed to implant a conventional arthroplasty) often lead to unreliable functional healing.<sup>5</sup> The third indication for reverse arthroplasty in our series was revision of a previous arthroplasty, where the cuff is deficient, scarred, or retracted or has undergone fatty infiltration (Figure 8).<sup>50</sup> In this study, we report the midterm results and complications of the Delta reverse prosthesis for these 3 etiologies. This study represents one of the largest Delta series to date, and it is the first to analyze the different underlying pathologies separately. Other strengths include examination by independent observers, minimal loss to follow-up (despite the advanced age of many patients), and detailed radiologic analysis of the state of both the cuff preoperatively and the prosthesis postoperatively.

Our study shows that the Delta reverse prosthesis can improve function and restore active elevation beyond the horizontal level in patients with severely cuff-deficient shoulders (Figure 6). Active rotation, however, is not improved. Thus far, the few published reports on the Delta are mostly small series, limited to a single pathology, usually CTA (Table V). Comparisons should be made cautiously, but the findings do appear to be consistent with ours. The mean values for the Constant score and active elevation in the 6 previous CTA series are all within the limits of our 95% confidence intervals for this group. In our experience, this prosthesis yields better results than traditional unconstrained shoulder arthroplasty in patients with CTA, but longer follow-up is required to determine the results' durability. Our reoperation rate of 5% for the CTA group also compares favorably with previous series.

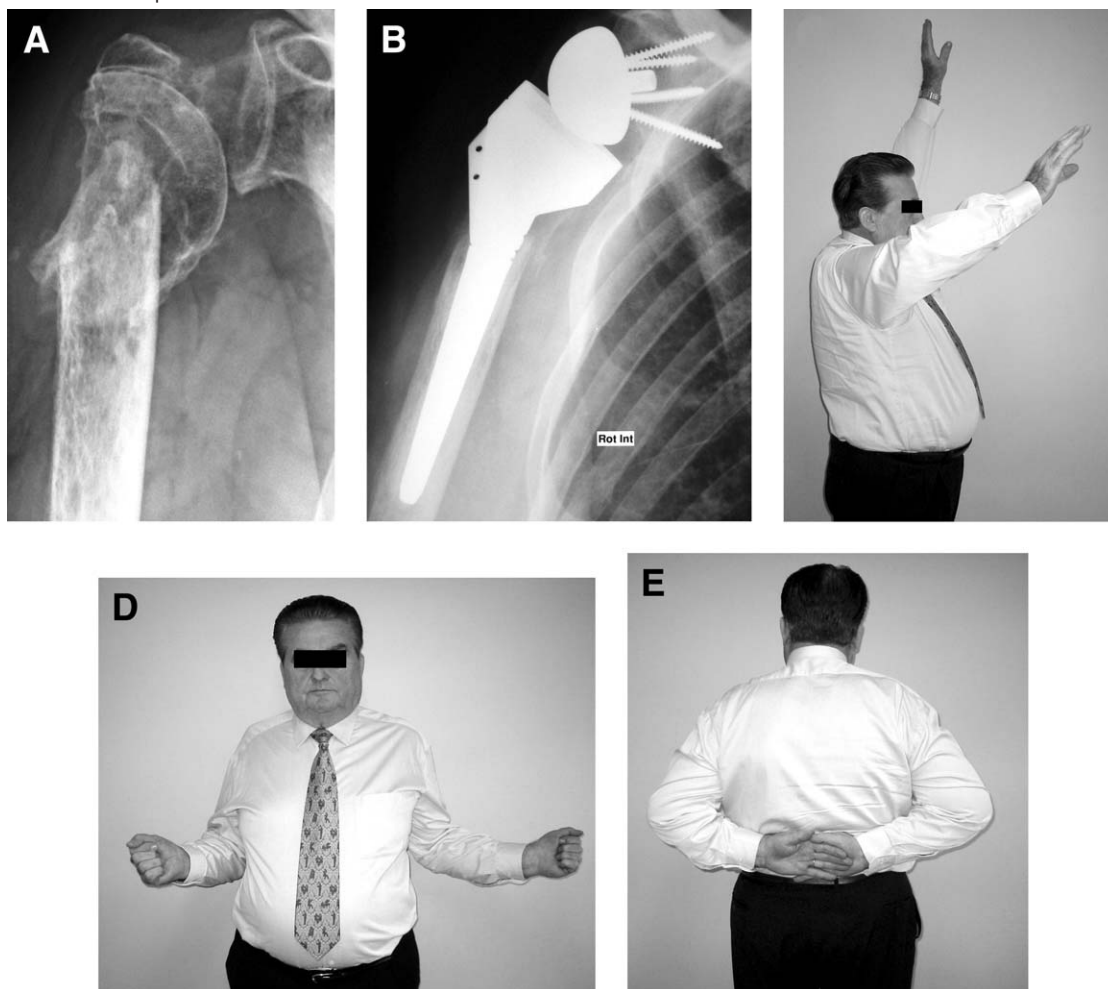
As one might expect, the functional results are not as good when the Grammont prosthesis is used in revision surgery, mainly because of the high rate of complications, reoperations, or revisions (Tables I and II). Both the Constant score and the ASES score were significantly lower in the revision group as compared with the CTA group, but there was no significant difference in active elevation in those who had no complications or revision (Figures 3 and 4). The vast majority of the complications in the series occurred in the revision group, and this was reflected in a 42% revision rate (8/19 patients). Although function may not have been as good as in the CTA group, those patients who did not require further revision had a

\*References 4, 8, 11, 29, 30, 31, 33, 39, 45, 51.





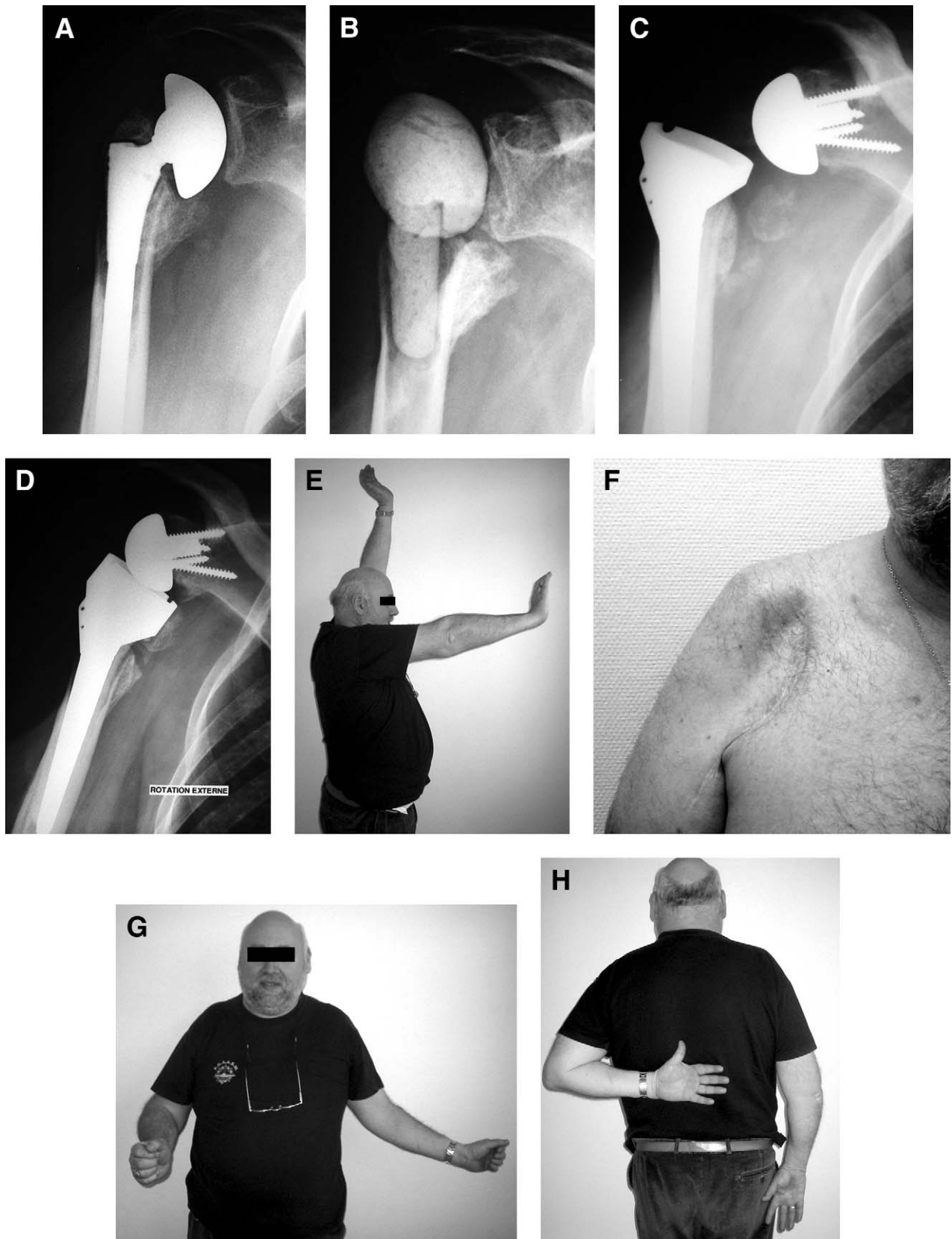**Figure 6** Results of reverse prosthesis for CTA. **A**, Preoperative anteroposterior view. **B**, Placement of Grammont reverse prosthesis. The patient had complete active elevation (**C**), but external rotation (**D**) and internal rotation (**E**) were not improved.



**Figure 7** Results of reverse prosthesis for FS. **A**, Preoperative anteroposterior radiograph showing CTA. **B**, Placement of Grammont reverse prosthesis. The patient had active elevation to about 120° (**C**). External rotation was not improved (**D**), whereas internal rotation was satisfactory (**E**).

significant increase in function and active elevation after the operation; furthermore, 13 of 16 believed that they had benefited from the procedure (Figure 8). Schnee-

berger and Gerber<sup>43</sup> have reported a similar experience with Grammont replacement for revision cases, with a high complication and revision rate of 50%.



**Figure 8** Revision of failed shoulder replacement (Bi-Polar) for fracture with infection. **A**, Tuberosity migration and infection. **B**, First step (prosthesis removal and spacer with antibiotics). **C**, Second step (placement of reverse prosthesis, which was complicated by dislocation after 2 months). **D**, Re-revision (addition of neck extension). The patient had active elevation to about 90° (**E**), despite an almost absent anterior deltoid because of the previous operation (**F**). External rotation (**G**) and internal rotation (**H**) remained limited.

**Table V** Published series for Grammont prosthesis

Author	No.	Pathology	Follow-up (mo)	Active elevation (preoperative/postoperative) (°)	Constant score (preoperative/postoperative)	Reoperation and revision rate
Grammont et al (1996) <sup>25</sup>	16	CTA	27	NA	14/69	13%
De Buttet et al (1997) <sup>13</sup>	71	CTA	24	NA/120	19.4/59.9	4.2%
De Wilde et al (2001) <sup>14</sup>	5	Revision	30	"Fair"	14/62	20%
Rittmeister et al (2001) <sup>40</sup>	8	RA	54	NA	17/63	37.5%
Jacobs et al (2001) <sup>28</sup>	7	CTA	16	NA	17.9/56.7	0%
Sirveaux et al (2001) <sup>44</sup>	80	CTA	44	73/138	22.6/65.6	5%
Valenti et al (2001) <sup>47</sup>	39	CTA	84	60/120	21/63	15%
Bouhahia et al (2002) <sup>7</sup>	16	CTA and FS	35	70/138	31/59	12.5%
Delloye et al (2002) <sup>16</sup>	5	Revision	81	NA/72	NA/40	60%
De Wilde et al (2002) <sup>15</sup>	6	Tumors	12	NA/106	NA	0%
Our series (2005)	45	CTA, FS, and Revision	40	55/121	17/58	22%

NA, Not available; RA, rheumatoid arthritis.

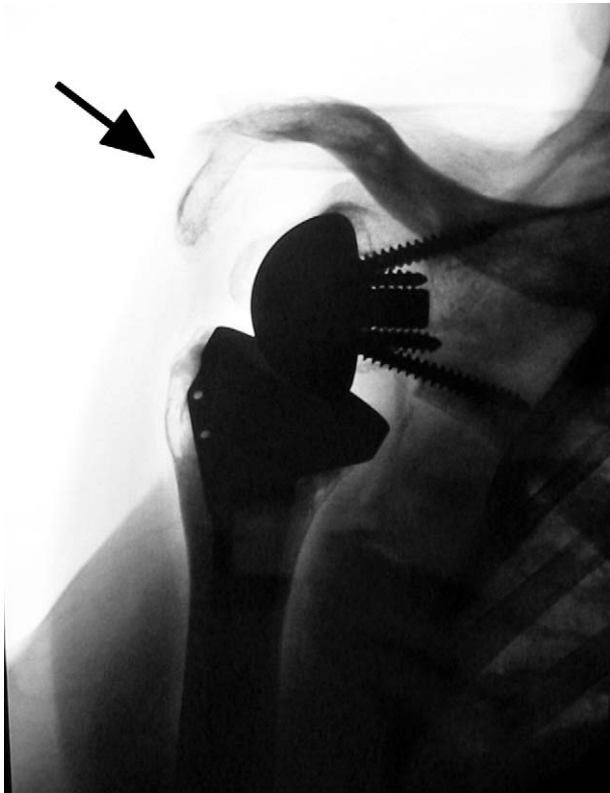
Although the Grammont prosthesis is able to restore active elevation, active external rotation remains an unsolved problem (Figure 6). A potential explanation for the weak external rotation after Grammont reverse prosthesis implantation is related to the medialization of the center of rotation and of the humerus. Because of this medialization, the amount of posterior deltoid that can be used to compensate for the absent external rotators is decreased.<sup>6</sup> The posterior deltoid does, theoretically, provide some external rotation power but only coupled with abduction.<sup>24</sup> Increasing the retroversion of the humeral component should improve external rotation, in theory, but only at the expense of internal rotation. In addition, the design of the prosthesis itself limits rotation: the humeral cup is limited in its rotation around the glenosphere and can impinge against the posterior neck of the scapula when the arm is at the side. Like other investigators, we have found that absence of severe fatty infiltration of the teres minor does confer superior external rotation, but even when this was the case, it still averaged only 15°. <sup>7,18,44</sup> Absence of active external rotation may be obvious clinically because of a persistent hornblower's sign.<sup>48</sup> Moreover, we found that severe fatty infiltration of the teres minor was associated with lower functional results (Constant score of 46 points vs 66 points,  $P < .007$ ).

A positive belly-press test was found in 22 patients postoperatively. Of these, 10 had a subscapularis tear preoperatively and 2 had grade 3 fatty infiltration of the subscapularis. The other 10, however, had an intact subscapularis muscle preoperatively, suggesting either failure of the subscapularis to heal or a limit inherent in the prosthetic ROM (because of the medialization). The subscapularis may be prone to failure of healing, as the Grammont prosthesis displaces the humerus inferiorly, relative to the scapula, theoretically increasing the tension on the subscapu-

laris tendon repair. This can be a significant complication in unconstrained shoulder arthroplasties, but we have not shown any significant effect on either ROM or functional results with the Grammont.<sup>50</sup>

The glenoid component is usually the main site of loosening in total shoulder arthroplasty, particularly with a constrained design.<sup>19,39</sup> There was only 1 case of early glenoid loosening in our series (the week after implantation), and it was associated with an intraoperative glenoid fracture, which compromised implant fixation. Although a longer follow-up is mandatory, glenoid loosening has not been encountered thus far. This confirms the value of Grammont's concept of medialization of the center of rotation.<sup>6,23,24</sup> A thin radiolucent line was seen in the superior part of the baseplate (zone 1) in 44% of glenoids, but none of these progressed, and this probably represents incomplete bony in-growth, a zone of fibrous tissue. In unconstrained total shoulder arthroplasties, such radiolucent lines have been reported in up to 80% of cemented glenoid components.<sup>18</sup> We encountered more difficulties with humeral loosening, although most of these cases were associated with low-grade infection.

Most of the complications observed are common to any shoulder prosthesis.<sup>50</sup> The Delta 3 prosthesis, however, seems prone to 3 specific problems related to its design: acromial fracture, dislocation, and scapular notching.<sup>6</sup> To compensate for the deficient cuff, adequate tension must be restored to the deltoid.<sup>24</sup> This is confirmed by a tight reduction and palpation of a taut conjoined tendon. The bone in these elderly patients is often osteoporotic, and excessive deltoid tension can result in acromial fracture (Figure 9). Fortunately, the 2 acromial fractures that we observed were both asymptomatic fatigue fractures, which did not compromise active elevation or abduction. At the other end of the spectrum, insufficient tension in the



**Figure 9** Acromial “fatigue” fracture related to overtensioning of deltoid in a patient with osteoporotic bone.

deltoid can result in prosthetic instability (Figure 8, C). Restoring deltoid tension may be difficult because the proximal epiphysis is often missing, especially after a failed prosthetic replacement for fracture with tuberosity migration and lysis. For these cases, we have learned to cement the prostheses proud from the remaining bone, so tension on the deltoid can be restored within available neck-lengthening options (Figure 7).

The scapular notch is another cause for concern, although very little has been published about it in the literature.<sup>3,18,44,47</sup> Two fundamental design principles of the Grammont prosthesis are (1) the absence of a neck on the reverse glenoid component, minimizing torque at the prosthesis-bone interface, and (2) a nonanatomic inclination of 155° of the humeral implant. These design aspects, crucial to its excellent function, are also responsible for impingement of the humeral cup on the inferior margin of the scapular neck.<sup>6</sup> The bony spur that we observed at the medial border of the notch (present in 68% of cases) may be a reactive process analogous to osteophyte formation in osteoarthritis (Figure 5). Although impingement may explain grade 1 or even grade 2 notches, it seems unlikely to be the direct cause of a notch extending beyond the inferior screw. A possible ex-

planation for such large notches is osteolysis induced by polyethylene debris released by the impingement. This phenomenon would also likely result in prosthetic loosening in the long term, as suggested recently by Nyffeler et al.<sup>35</sup> Nonetheless, we have not observed glenoid osteolysis with up to 7 years’ follow-up, except in the region of the notch. In a longer-term report on the Grammont prosthesis, Valenti et al<sup>47</sup> also observed no progression of notches to glenoid loosening at a mean of 7 years postoperatively. To minimize notching, our current practice is to insert the glenoid component as low as possible.<sup>36</sup> Biomechanical studies and refinement in prosthetic technique and design hopefully will decrease the rate of complications.

Finally, low-grade, indolent infection is another serious complication that is associated with revision surgery. It occurred in 3 of our patients and resulted in resection arthroplasty in 2 of them. When revising a failed prosthesis, surgeons must be aware that low-grade infection can be present without overt clinical symptoms or signs.<sup>12</sup> Our preoperative evaluation of these patients always includes assessment of the complete blood count with differential, erythrocyte sedimentation rate, and C-reactive protein level, as well as a 3-phase bone scan. Intraoperatively, specimens are sent for culture and frozen section analysis. If an infection is discovered or highly suspected, our current practice is to perform a 2-step procedure. The first operation entails removal of the prosthesis, aggressive irrigation and debridement, and placement of an antibiotic cement spacer. This is followed by implantation of a reverse prosthesis in 6 weeks, only if laboratory tests and intraoperative frozen sections suggest that the infection has been cleared. Four patients had a 2-stage procedure to revise an infected conventional arthroplasty to a reverse arthroplasty; none of them had a recurrent infection at the latest follow-up.

In summary, the reverse prosthesis can improve function and restore active elevation in patients with incongruent cuff-deficient shoulders. Improvement in active rotation, however, does not usually occur. At midterm follow-up, glenoid loosening has not occurred. Our clinical results of the Grammont reverse prosthesis differentiate it from the reverse ball-and-socket designs of the past and live up to the biomechanical concept of Paul Grammont. These results are, furthermore, an improvement on Neer’s limited goals in patients with cuff-deficient arthritis. Our study also shows that this prosthesis offers a solution for other difficult clinical situations: failure of previous prostheses and severe FS with an absent or nonfunctional cuff. However, results are clearly less predictable and complication and revision rates are higher in those patients as compared with CTA patients. These clinical results support the use of this prosthesis



for patients with severe pain from significant unrepairable cuff deficiency, arthritis, and a lack of a stable fulcrum for shoulder elevation. In revision surgery, we are very wary of occult infection, even in the absence of obvious clinical symptoms or signs. Caution is required, as such patients are often younger, and informed consent must obviously cover the high complication rate in this group, as well as the unknown longer-term outcome. On the basis of the current design and results, the reverse prosthesis should be considered a salvage procedure: its use should be limited to elderly patients, arguably those aged over 70 years, with poor function and severe pain related to cuff deficiency. A reverse prosthesis should not be offered to a young individual who desires to have a normal shoulder and will demand more of the prosthesis than it is designed to do.<sup>16</sup> Results of the reverse prosthesis depend on the diagnosis and the remaining cuff muscles, specifically the teres minor.

## REFERENCES

1. Arntz CT, Jackins S, Matsen FA III. Prosthetic replacement of the shoulder for the treatment of defects in the rotator cuff and the surface of the glenohumeral joint. *J Bone Joint Surg Am* 1993; 75:485-91.
2. Barrett WP, Franklin JL, Jackins SE, Wyss CR, Matsen FA. Total shoulder arthroplasty. *J Bone Joint Surg Am* 1987;69:865-72.
3. Baulot E, Chabernaud D, Grammont P. Results of Grammont's inverted prosthesis in omarthritis associated with major cuff destruction. Apropos of 16 cases [in French]. *Acta Orthop Belg* 1995;61(Suppl II):112-9.
4. Bayley JLL, Kessel L. The Kessel total shoulder replacement. In: Bayley J, Kessel L, editors. *Shoulder surgery*. Berlin: Springer; 1982.
5. Boileau P, Trojani C, Walch G, Krishnan SG, Romeo A, Sinner-ton R. Shoulder arthroplasty for the treatment of the sequelae of fractures of the proximal humerus. *J Shoulder Elbow Surg* 2001; 10:299-308.
6. Boileau P, Watkinson DJ, Hatzidakis AM, Balg F. Grammont reverse prosthesis: design, rationale, and biomechanics. *J Shoulder Elbow Surg* 2005;14(Suppl S):147S-61S.
7. Boulahia A, Edwards TB, Walch G, Baratta RV. Early results of a reverse design prosthesis in the treatment of arthritis of the shoulder in elderly patients with a large rotator cuff tear. *Orthopedics* 2002;25:129-33.
8. Broström LÅ, Wallenstein R, Olsson E, Anderson D. The Kessel prosthesis in total shoulder arthroplasty. A five-year experience. *Clin Orthop Relat Res* 1992;155-60.
9. Cofield RH. Total shoulder arthroplasty with the Neer prosthesis. *J Bone Joint Surg Am* 1984;66:899-906.
10. Constant CR, Murley AHG. A clinical method of functional assessment of the shoulder. *Clin Orthop Relat Res* 1987;160-4.
11. Coughlin MJ, Morris JM, West WF. The semiconstrained total shoulder arthroplasty. *J Bone Joint Surg Am* 1979;61:574-81.
12. Coste JS, Reig S, Trojani C, Berg M, Walch G, Boileau P. The management of infection in arthroplasty of the shoulder. *J Bone Joint Surg Br* 2004;86:65-9.
13. De Butté A, Bouchon Y, Capon D, Delfosse J. Grammont shoulder arthroplasty for osteoarthritis with massive rotator cuff tears—report of 71 cases [abstract]. *J Shoulder Elbow Surg* 1997;6: 197.
14. De Wilde L, Mombert M, Van Petegem P, Verdonk R. Revision of shoulder replacement with a reversed shoulder prosthesis (Delta III). Report of five cases. *Acta Orthop Belg* 2001;67:348-53.
15. De Wilde LF, Van Ovost E, Uyttendaele D, Verdonk R. Results of an inverted shoulder prosthesis after resection for tumor of the proximal humerus [in French]. *Rev Chir Orthop Reparatrice Appar Mot* 2002;88:373-8.
16. Delloye C, Joris D, Colette A, Eudier A, Dubuc J. Mechanical complications of total shoulder inverted prosthesis [in French]. *Rev Chir Orthop Reparatrice Appar Mot* 2002;88:410-4.
17. Edwards TB, Boulahia A, Kempf JF, Boileau P, Nemoz C, Walch G. The influence of the rotator cuff on the results of shoulder arthroplasty for primary osteoarthritis: results of a multicenter study. *J Bone Joint Surg Am* 2002;84:2240-8.
18. Favard L, Lautmann S, Sirveaux F, Oudet D, Kerjean Y, Huguet D. Hemi arthroplasty versus reverse arthroplasty in the treatment of osteoarthritis with massive rotator cuff tear. In: Walch G, Boileau P, Molé D, editors. *2000 Shoulder prosthesis . . . two to ten year follow-up*. Montpellier, France: Sauramps Medical; 2001. p. 261-8.
19. Fenlin JM. Total glenohumeral joint replacement. *Orthop Clin North Am* 1975;6:565-83.
20. Field LD, Dines DM, Zabinski SJ, Warren RF. Hemiarthroplasty of the shoulder for rotator cuff arthropathy. *J Shoulder Elbow Surg* 1997;6:18-23.
21. Franklin JL, Barrett WP, Jackins SE, Matsen FA III. Glenoid loosening in total shoulder arthroplasty. Association with rotator cuff deficiency. *J Arthroplasty* 1988;3:39-46.
22. Goutallier D, Postel JM, Bernageau J, Lavau L, Voisin MC. Fatty muscle degeneration in cuff ruptures. Pre- and postoperative evaluation by CT scan. *Clin Orthop Relat Res* 1994;78-83.
23. Grammont P, Trouilloud P, Laffay JP, Deries X. Etude et réalisation d'une nouvelle prothèse d'épaule. *Rhumatologie* 1987;39:17-22.
24. Grammont PM, Baulot E. Delta shoulder prosthesis for rotator cuff rupture. *Orthopaedics* 1993;16:65-8.
25. Grammont PM, Baulot E, Chabernaud D. Résultats des 16 premiers cas d'arthroplastie totale d'épaule inversée sans ciment pour des omarthroses avec grande rupture de coiffe [abstract]. *Rev Chir Orthop Reparatrice Appar Mot* 1996;82(Suppl II):169.
26. Hadzidakis A, Norris T, Boileau P. Reverse shoulder arthroplasty indications, technique, and results. *Tech Shoulder Elbow Surg* 2005;6:135-49.
27. Hamada K, Fukuda H, Mikasa M, Kobayashi Y. Roentgenographic findings in massive rotator cuff tears. A long-term observation. *Clin Orthop Relat Res* 1990:92-6.
28. Jacobs R, Debeer P, De Smet L. Treatment of rotator cuff arthropathy with a reversed Delta shoulder prosthesis. *Acta Orthop Belg* 2001;67:344-7.
29. Kölbl R, Friedebold G. Stabilization of shoulders with bone and muscle defects using joint replacement implants. In: Bateman J, Welsh P, editors. *Shoulder surgery*. At Louis: Mosby. p. 281-7.
30. Lee DH, Niemann KM. Bipolar shoulder arthroplasty. *Clin Orthop Relat Res* 1994:97-107.
31. Lettin A, Copeland S, Scales J. The Stanmore total shoulder replacement. *J Bone Joint Surg Br* 1982;64:47-51.
32. Levine WN, Djurasovic M, Glasson JM, Pollock RG, Flatow EL, Bigliani LU. Hemiarthroplasty for glenohumeral osteoarthritis: results correlated to degree of glenoid wear. *J Shoulder Elbow Surg* 1997;6:449-54.
33. McElwain J, English E. The early results of porous coated total shoulder arthroplasty. *Clin Orthop Relat Res* 1987:217-24.
34. Neer CS, Watson KC, Stanton FJ. Recent experience in total shoulder replacement. *J Bone Joint Surg Am* 1982;64:319-37.
35. Nyffeler RW, Werner CM, Simmen BR, Gerber C. Analysis of a retrieved Delta III total shoulder prosthesis. *J Bone Joint Surg Br* 2004;86:1187-91.
36. Nyffeler RW, Werner CM, Gerber C. Biomechanical relevance of glenoid component positioning in the reverse Delta III total shoulder prosthesis. *J Shoulder Elbow Surg* 2005;14:524-8.
37. Pollock RG, Deliz ED, McIlveen SJ, Flatow EL, Bigliani LU. Prosthetic replacement in rotator cuff deficient shoulders. *J Shoulder Elbow Surg* 1992;1:173-86.

38. Poppen NK, Walker PS. Forces at the glenohumeral joint in abduction. *Clin Orthop Relat Res* 1978;165:70.
39. Post M, Haskell SS, Jablon M. Total shoulder replacement with a constrained prosthesis. *J Bone Joint Surg Am* 1980;62:327-35.
40. Rittmeister M, Kerschbaumer F. Grammont reverse total shoulder arthroplasty in patients with rheumatoid arthritis and nonreconstructible rotator cuff lesions. *J Shoulder Elbow Surg* 2001;10:17-22.
41. Sanchez-Sotelo J, O'Driscoll SW, Torchia ME, Cofield RH, Rowland CM. Radiographic assessment of cemented humeral components in shoulder arthroplasty. *J Shoulder Elbow Surg* 2001;10:526-31.
42. Sanchez-Sotelo J, Cofield RH, Rowland CM. Shoulder hemiarthroplasty for glenohumeral arthritis associated with severe rotator cuff deficiency. *J Bone Joint Surg Am* 2001;83:1814-22.
43. Schneeberger A, Gerber C. Complications with the Delta reversed prosthesis [abstract]. Presented at the ASES Closed Meeting 2004.
44. Sirveaux F, Favard L, Oudet D, Huguet D, Lautman S. Grammont inverted total shoulder arthroplasty in the treatment of glenohumeral osteoarthritis with massive and non repairable cuff rupture. In: Walch G, Boileau P, Molé D, editors. 2000 Shoulder prosthesis . . . two to ten year follow-up. Montpellier: Sauramps Medical; 2001. p. 247-52.
45. Swanson AB, de Groot Swanson G, Sattel AB, Cendo RD, Hynes D, Jar-Ning W. Bipolar implant shoulder arthroplasty. Long-term results. *Clin Orthop Relat Res* 1989;227-47.
46. Torchia ME, Cofield RH, Settegren CR. Total shoulder arthroplasty with the Neer prosthesis: long-term results. *J Shoulder Elbow Surg* 1997;6:495-505.
47. Valenti PH, Boutens D, Nerot C. Delta 3 reversed prosthesis for arthritis with massive rotator cuff tear: long term results (> 5 years). In: Walch G, Boileau P, Molé D, editors. 2000 Shoulder prosthesis . . . two to ten year follow-up. Montpellier: Sauramps Medical; 2001. p. 253-9.
48. Walch G, Madonia G, Pozzi I, Riand N, Lévine C. Arthroscopic tenotomy of the tendon of the long head of the biceps in rotator cuff ruptures. In: Gazielly D, Gleyze P, Thomas T, editors. The cuff. Amsterdam: Elsevier; 1997. p. 350-5.
49. Walch G, Boulahia A, Calderone S, Robinson AHN. The dropping and hornblower's signs in evaluation of rotator cuff tears. *J Bone Joint Surg Br* 1998;80:624-8.
50. Williams GR Jr, Rockwood CA Jr. Hemiarthroplasty in rotator cuff-deficient shoulders. *J Shoulder Elbow Surg* 1996;5:362-7.
51. Wirth MA, Rockwood CA Jr. Current concepts review. Complications of total shoulder arthroplasty. *J Bone Joint Surg Am* 1996;78:603-16.
52. Worland RL, Jessup DE, Arredondo J, Warburton KJ. Bipolar shoulder arthroplasty for rotator cuff arthropathy. *J Shoulder Elbow Surg* 1997;6:512-5.